

Clinical Science

Small bowel obstruction in the virgin abdomen: the need for a mandatory laparotomy explored



Christian Beardsley, M.B.B.S., Ruelan Furtado, M.B.B.S., Charles Mosse, F.R.A.C.S., Sivakumar Gananadha, F.R.A.C.S., James Fergusson, F.R.A.C.S., Phil Jeans, F.R.A.C.S., Edwin Beenen, M.D.*

Upper GI/HPB Unit, Department of Surgery, The Canberra Hospital, Yamba Drive, Garran, ACT 2605, Australia

KEYWORDS:

Intestinal obstruction;
Small intestine;
Tissue adhesion;
Laparotomy

Abstract

BACKGROUND: A laparotomy is still considered mandatory for patients without previous abdominal surgery presenting with a small bowel obstruction (SBO) because of a perceived high incidence of underlying lesions. However, there is no evidence in literature to support this assumption. We analyzed the etiology of SBO in this subgroup of patients to establish the need for a mandatory laparotomy.

METHODS: A retrospective analysis was conducted over a 5-year period. Basic demographics, radiology results, operative findings, and outpatient investigations were analyzed.

RESULTS: Of 689 patients presenting with an SBO, a total of 62 patients, 9.0%, had a virgin abdomen. A known underlying disease (inflammatory bowel disease, malignancy) was the cause in 13 patients. The remaining 49 patients had adhesions in 75.5% and a newly diagnosed malignancy in 10.2% as a cause.

CONCLUSIONS: Adhesions are by far the most likely cause of SBO in patients without previous abdominal surgery followed by a small number of newly diagnosed malignancies. Both prevalences are in equal proportion to patients with previous abdominal surgery. A trial of nonoperative management may therefore be justified.

© 2014 Elsevier Inc. All rights reserved.

“Never let the sun set or rise on a small bowel obstruction (SBO)” is a surgical dogma which has been widely taught.¹⁻³ In more recent years, management has carefully shifted toward a nonoperative approach for patients with previous abdominal surgery in whom adhesions are considered the main cause for obstruction.^{1,2}

However, a subgroup of patients presenting with SBO will not have had any abdominal surgery in the past (virgin abdomen) and in them a laparotomy is still considered mandatory by some large centers.^{1,4} The underlying

reasoning being that the SBO would likely be caused by an obstructive lesion.¹ There is, however, a paucity of evidence regarding the underlying causes of SBO in patients without previous abdominal surgery to justify any management protocol.

We therefore undertook a retrospect review of all our patients admitted with SBO and focused on the subgroup of patients with virgin abdomens to determine the causes of SBO, their prevalence, and the role of computed tomography (CT) of the abdomen in diagnosis and as a guide to operative management. We hypothesized that the need for a mandatory laparotomy in patients without previous abdominal surgery presenting with an SBO would be guided by the prevalence of the underlying etiologies and the ability of the CT-abdomen to identify these underlying causes.

There were no relevant financial relationships or any sources of support in the form of grants, equipment, or drugs.

* Corresponding author. Tel.: +61-2-6244 2222; fax: +61-2-6205-2157.

E-mail address: edwinbeenen@gmail.com

Manuscript received July 5, 2013; revised manuscript August 30, 2013

Methods

The Canberra Hospital is the only tertiary referral hospital in the Australian Capital Territory and surrounding New South Wales area and one of only 2 hospitals providing acute surgical care.

A retrospective analysis was conducted from January 1, 2007 to December 31, 2011. Patients were identified from the Medical Records Department by ICD-10 codes. The ICD-10 codes are applied throughout the entire admission, so both the initial working diagnosis on admission as the final diagnosis on discharge as any other additional diagnosis made during the admission are coded and recorded.

Included were all patients who presented to the Emergency Department with symptoms and signs of an acute gastrointestinal obstruction, were 16 years or older, had no previous abdominal surgery, and had a confirmed SBO on plain abdominal films or CT-abdomen. Patients with ileus, other forms of gastrointestinal obstructions (eg, colonic obstruction or incarcerated external hernia), or a past history of abdominal surgery were excluded.

A sudden onset of abdominal discomfort or pain with nausea and vomiting combined with distension of the abdomen and absent flatus was considered a typical presentation of a gastrointestinal obstruction.⁵ Dilated loops of small bowel with air-fluid levels and an absent colonic gas pattern were considered as confirmation of an SBO by plain abdominal films.^{1,5-8} An SBO on CT-scan would show dilated proximal small bowel, a possible transition point, and collapsed small bowel distally.^{1,5,6} Previous abdominal surgery was defined as any operation that would have breached the peritoneum.

Since no guidelines exist regarding the management of an SBO in patients with a virgin abdomen, the management was at the discretion of the admitting surgeon. The absence of previous abdominal surgery and the assumption of underlying pathology might have favored an operative approach in these patients. Follow-up investigations were again at the discretion of the admitting surgeon, but again no standard recommendations exist. Being a retrospect study, the exact/in-detail reasoning for a final management approach was difficult to be extracted from the medical records.

Basic demographics of age and sex were collected for all patients admitted with SBO. Of the patients without previous abdominal surgery, medical history, radiology results, operative findings, pathology results, and results of further investigations following discharge were collected. The final diagnosis was primarily based on the operative findings. For nonoperated patients, the final diagnosis was based on the findings of all investigations. If no underlying lesions or other causes could be identified by any of the further investigations, by exclusion adhesions would be concluded.

The accuracy of the CT-abdomen was calculated by comparing the radiological diagnosis with the final

diagnosis, either made at laparotomy or by further investigations.

Statistical analysis for basic demographics was performed using StatView 5.0.1 (SAS Institute Inc, Cary, NC). Statistical difference was computed for continuous data using the Mann-Whitney *U* test and the chi-square test and Fisher's exact test for categorical data. A *P* value of $<.05$ was considered statistically significant.

Medical ethical approval of this study was obtained from the Human Research Ethics Committee, ACT Government Health Directorate.

Results

From January 1, 2007 to December 31, 2011, 854 patients were identified by ICD-10 codes. An SBO was diagnosed in 689 patients. Of these 62 patients, 9.0% (62/689) of patients had no previous abdominal surgery and formed the study population.

The 62 patients consisted of 21 women and 41 men with a median age of 66 years (range, 18 to 91). Their median age was similar to the patients with previous abdominal surgery (66 years [range, 16 to 97]; $P = .621$), but men were more frequently represented (66.1% vs 49.0%; $P = .011$). A CT-abdomen was performed in 93.5% (58/62) of patients. A laparotomy was undertaken in 61.3% (38/62) of patients. Ischemic small bowel with the subsequent need for bowel resection was found in 5 patients. The final diagnosis of all 62 patients is presented in the flowchart (Fig. 1).

Etiology of small bowel obstruction

A previously diagnosed disease was identified to be the cause of SBO in 13 patients. In 7 patients, a known metastatic disease (colorectal cancer, $n = 4$; prostate cancer, $n = 1$; gastric cancer, $n = 1$; melanoma, $n = 1$) was the cause of the SBO; 3 patients required a laparotomy, 2 patients were palliated, and 2 patients recovered on nonoperative management. Of the 6 patients with known Crohn's disease, only 1 patient required an ileocecal resection, the others were treated medically.

In 49 patients, no previously diagnosed disease as a possible underlying cause for the SBO was present. A laparotomy was performed in 34 patients (69.4%).

Adhesions were the most common cause of obstruction in these 49 patients with a prevalence of 75.5% (37/49). In 25 patients, the adhesions were proven at laparotomy [adhesions at laparotomy 73.5% (25/34)]. An additional phytobezoar and small bowel volvulus were found during laparotomy in 2 patients, both unrecognized by CT-abdomen.

In the absence of a previous disease or any underlying pathology found on CT-abdomen or further investigations in 12 patients, the diagnosis of adhesions was made by

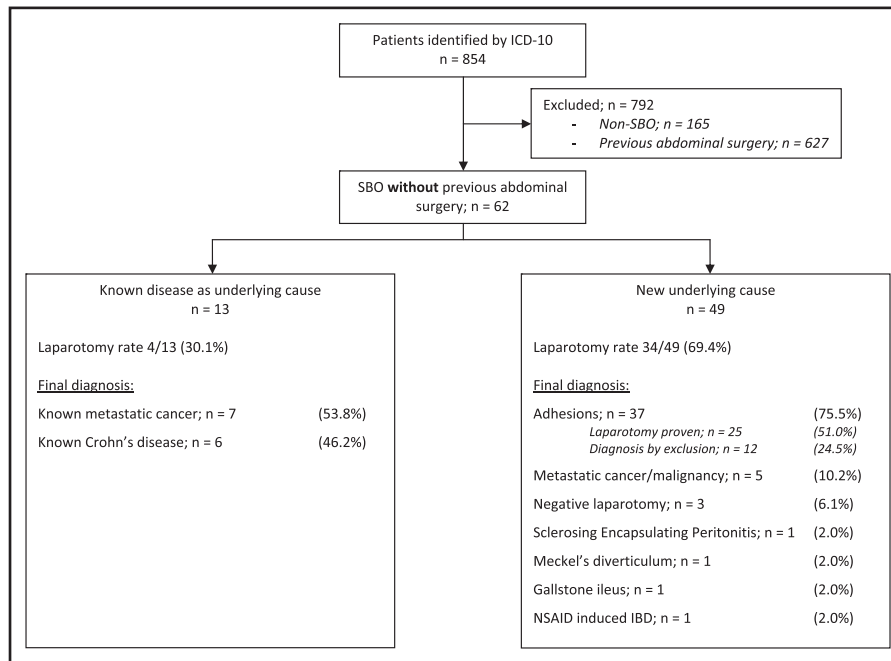


Figure 1 Flowchart: final diagnosis in patients without previous abdominal surgery presenting with small bowel obstruction.

exclusion. All recovered without any adverse events with nonoperative management. Eight patients were elderly with multiple comorbidities and unfit for surgery. Two of these patients had an SBO confirmed on plain abdominal films but not by CT-abdomen. In follow-up, 2 elderly patients had a normal small bowel follow-through, 1 patient had a normal colonoscopy, and a 4th patient refused any further investigation. The remaining 4 elderly patients had no further investigations ordered.

The other 4 patients all had the SBO confirmed by CT-abdomen. A sigmoid mass and a small bowel volvulus were suggested in 2 patients. On follow-up, they both had a normal colonoscopy. The 3rd patient, without an underlying cause identified by CT-abdomen, had a normal small bowel follow-through and a normal colonoscopy. Finally, the 4th patient was transferred from a rural hospital with an SBO confirmed on plain films. On arrival in our hospital his SBO had resolved spontaneously and therefore there was no need to perform a CT-abdomen. After transfer to his base hospital, he was lost to follow-up. At the last follow-up date of June 30, 2013, none of these 12 patients have returned to our hospital or the other hospital with an SBO thus far, median follow-up 2.3 years (range, 1.6 to 4.5).

The 2nd most common underlying cause of SBO was a malignancy, which represented 10.2% (5/49) of newly diagnosed causes of SBO. A metastatic malignancy was recognized by CT-abdomen in 6.1% (3/49; colorectal cancer, $n = 1$; lung cancer, $n = 1$; pancreatic cancer, $n = 1$) of patients. Only in 2 patients, 4.1% (2/49), was the malignancy unrecognized by the CT-abdomen and diagnosed at the time of laparotomy (jejunal adenocarcinoma, $n = 1$; lymphoma, $n = 1$). The 2 patients represented 3.2% (2/62) of the overall patient group and 8.7% (2/23)

of patients without an underlying cause identified by CT-abdomen who underwent a laparotomy.

In 3 patients with a CT-abdomen confirming SBO but no underlying cause identified, no SBO or any other pathology was found at laparotomy. The 3 patients, 6.1% (3/49), formed the 3rd largest subgroup.

Miscellaneous causes for the SBO were a Meckel's diverticulum ($n = 1$), a gall stone ileus ($n = 1$) found during laparotomy, and a non-steroidal anti-inflammatory drug-induced ulceration and stricturing of the jejunum ($n = 1$) proven by follow-up video capsule and balloon endoscopy; all 3 recognized by CT-abdomen. Sclerosing encapsulating peritonitis ($n = 1$) was unrecognized by CT-abdomen and found on laparotomy.

Diagnostic role of computed tomography abdomen

A CT-scan was performed in 93.5% (58/62) of all patients. The CT-abdomen confirmed a known disease as the underlying cause in 10 patients (metastatic malignancy, $n = 5$; Crohn's disease, $n = 5$). In 3 patients with a known underlying disease, no CT-scan was performed (known metastatic malignancy [colon and stomach], $n = 2$; known Crohn's disease, $n = 1$).

Among the 49 patients without a previous diagnosis, 98.0% (48/49) underwent a CT-abdomen; only the transferred patient who's SBO had resolved on arrival to our hospital did not have a CT-abdomen ordered.

A laparotomy was performed in 69.4% of these patients and the CT-abdomen diagnosis could thus be compared with the operative findings in 34 patients. The laparotomy

Table 1 CT-abdomen accuracy in 34 patients who had a CT-abdomen followed by a laparotomy

CT-abdomen diagnosis (<i>n</i>)	Findings at laparotomy (<i>n</i>)	Inaccurate or missed CT-abdomen diagnosis	Correct CT-abdomen diagnosis
Underlying cause suggested (<i>n</i> = 11)			
Inflammatory bowel disease (<i>n</i> = 4)	Adhesions (<i>n</i> = 3)	3	
	Adhesions + phytobezoar (<i>n</i> = 1)	1	
Small bowel volvulus (<i>n</i> = 3)	Adhesions (<i>n</i> = 3)	3	
Metastatic cancer (<i>n</i> = 1)	Metastatic cancer (<i>n</i> = 1)		1
Intussusception (<i>n</i> = 1)	Adhesions (<i>n</i> = 1)	1	
Meckel's diverticulum (<i>n</i> = 1)	Meckel's diverticulum (<i>n</i> = 1)		1
Gallstone ileus (<i>n</i> = 1)	Gallstone ileus (<i>n</i> = 1)		1
No underlying cause identified (<i>n</i> = 23)			
SBO not confirmed (<i>n</i> = 1)	Adhesions (<i>n</i> = 1)	1	
SBO confirmed, no underlying cause identified, adhesions by exclusion (<i>n</i> = 22)	Adhesions (<i>n</i> = 15)		15
	Adhesions + small bowel volvulus (<i>n</i> = 1)	1	
	Negative laparotomy (<i>n</i> = 3)	3	
	Malignancy (<i>n</i> = 2)	2	
	Sclerosing encapsulating peritonitis (<i>n</i> = 1)	1	
Total (<i>n</i> = 34)		16/34 (47.1%)	18/34 (52.9%)

All 34 patients admitted with SBO in a virgin abdomen without a previously known disease as underlying cause. CT = computed tomography; SBO = small bowel obstruction.

confirmed diagnostic accuracy of CT-abdomen was 52.9% (18/34) with the CT-abdomen over diagnosing in 9 patients and missing a diagnosis in 7 patients (Table 1).

Of the remaining 14 patients with a CT-abdomen who were treated nonoperatively, no further investigations were performed in 5 elderly patients who were unfit for surgery. In 3 patients only a colonoscopy was ordered but the small bowel was not further investigated. The accuracy of the CT-abdomen for these 14 patients could therefore not be determined (Table 2).

Two elderly patients had an SBO confirmed on plain abdominal films but not by CT-abdomen. The delay between the plain films taken at admission and the performance of the CT-abdomen the day after might be a possible explanation.

Comments

The management of SBO remains a challenge to the surgeon. In patients with previous abdominal surgery adhesions are the most common cause of SBO. A nonoperative management has been the preferred method in recent years, carefully observing for nonresolving SBO or the development of strangulation and bowel ischemia.

SBO in patients without previous abdominal surgery, or so-called "virgin abdomen," is considered a further challenge since adhesions are assumed to be an unlikely

cause.^{1,9} Therefore, a mandatory laparotomy in this patient group is still recommended by some major centers.^{1,4} However, very little evidence to support this policy is found in literature.

This study has shown that adhesions are the most likely cause of SBO in patients with virgin abdomens. In our series, adhesions caused 75.5% of the SBO in patients with virgin abdomens without a known underlying disease. A similar rate of adhesions is found in patients with previous abdominal surgery with prevalence reported up to 80% if incarcerated external hernias are excluded.^{2,10,11}

Adhesions as a cause for SBO in virgin abdomens were considered normal in the past and still considered more common in the developing world as a result of intra-abdominal infections (eg, tuberculosis, typhlitis, or dysentery).^{1,12} Although these infectious diseases are now uncommon within the Western World,¹² a (subclinical) intra-abdominal infection might still be an explanation for the formation of adhesions.⁶ A congenital formation would be another theory, although both theories remain speculative.

We have presented the largest series so far of SBO in virgin abdomen focusing on the distribution of causes. Smaller case series of benign causes like internal herniations¹³ or congenital band adhesions¹⁴ have been reported just like larger series of SBO including virgin abdomens with a variety of causes.¹⁵ However, none of them focused on the distribution of these causes to guide the clinician or as a justification of mandatory surgical management. There

Table 2 CT-abdomen accuracy in 14 patients without a previously known disease as underlying cause who had a CT-abdomen and were treated nonoperatively

CT diagnosis (<i>n</i>)	Further investigations (<i>n</i>)	Final diagnosis (<i>n</i>)	Inaccurate or missed CT-abdomen diagnosis	Correct CT-abdomen diagnosis
Underlying cause suggested				
Inflammatory bowel disease (<i>n</i> = 1)	Video capsule + balloon endoscopy (<i>n</i> = 1)	NSAID-induced IBD		1
Small bowel volvulus (<i>n</i> = 1)	Colonoscopy, normal (<i>n</i> = 1)	Adhesions (<i>n</i> = 1)	x	x
Metastatic cancer (<i>n</i> = 2)	Biopsies (<i>n</i> = 2)	Metastatic cancer (<i>n</i> = 2)		2
Sigmoid mass (<i>n</i> = 1)	Colonoscopy, normal (<i>n</i> = 1)	Adhesions (<i>n</i> = 1)	1	
No underlying cause identified				
SBO not confirmed (<i>n</i> = 2)	None (<i>n</i> = 2)	x	x	x
SBO confirmed, no underlying cause identified, adhesions by exclusion (<i>n</i> = 7)	Small bowel follow-through, normal (<i>n</i> = 2)	Adhesions (<i>n</i> = 2)		2
	Colonoscopy, normal (<i>n</i> = 1)	Adhesions (<i>n</i> = 1)	x	x
	Small bowel follow-through + colonoscopy, normal (<i>n</i> = 1)	Adhesions (<i>n</i> = 1)		1
Total (<i>n</i> = 14)	None (<i>n</i> = 3)	Adhesions (<i>n</i> = 1)	x	x
			1	6

CT = computed tomography; IBD = inflammatory bowel disease; NSAID = non-steroidal anti-inflammatory drug; SBO = small bowel obstruction; x = no or inappropriate follow-up studies of small bowel to compare with CT-abdomen findings.

are only 2 series that focus on the distribution of causes of bowel obstruction in virgin abdomen patients, but both series included both small and large bowel obstructions.^{4,9} In both series, colonic malignancies were by far the leading cause for large bowel obstructions,^{4,9} although McCloy et al⁴ did not segregate his series into large and small bowel obstructions. Furthermore, only 3 of the 28 patients from his series underwent a CT-abdomen.⁴

The findings in the more detailed series of Omori et al⁹ confirmed (congenital band) adhesions or internal herniation as the main cause of SBO in the virgin abdomen. They only found an underlying malignancy in 8.1% (3/37) of their virgin abdomen SBO, consisting of an adenocarcinoma and 2 lymphomas. Although our series overall showed an underlying malignancy in 19.4% of the patients (12/62), over half of these malignancies were diagnosed before the occurrence of the SBO. Only 10.2% (5/49) of our patients without a known disease had a newly diagnosed malignancy; 3 were diagnosed by CT-abdomen and 2 were identified at laparotomy. Among patients with previous abdominal surgery, a similar prevalence of an underlying malignancy of 3% to 20% has been reported.^{1,2,5} The most common intra-abdominal malignancies causing SBO being colon and ovarian cancer,^{1,16} and less commonly

secondary deposits from lobular breast cancer, melanoma, or lung cancer.¹⁷

Inflammatory bowel disease is recognized as the 3rd leading cause for all cases of SBO with a reported incidence of 5%.⁵ In our series overall, it was the 3rd leading cause as well albeit that the inflammatory bowel disease was already diagnosed before the occurrence of the SBO. It could mostly be managed with medication.¹

The accuracy of 52.9% of CT-abdomen in the diagnosis of SBO in the virgin abdomen is disappointing. Since adhesions can only be diagnosed by exclusion on CT-abdomen,⁶ the absence of previous surgery and the assumption of an underlying cause may have pressured the radiologist to over diagnose a possible cause for the SBO. Conversely, the diagnosis of adhesions by exclusion has to be taken with caution since the CT was under-reporting as well. Unfortunately, not all patients had further imaging of the small bowel to confirm the CT diagnosis of adhesions. However, none of these patients have represented so far, although it has to be remembered that 8 of 12 patients were elderly and unfit for surgery and 1 patient was lost to follow-up and this might have prevented their representation to the Canberra hospitals. Omori et al⁹ have shown the same difficulty in obtaining a correct

preoperative diagnosis for SBO in virgin abdomens, which they only were able to establish in 27% of cases, compared to a correct preoperative diagnosis of over 90% for their large bowel obstructions.

Many reviewers have confidently described the appearances of a variety of small bowel pathologies on CT-abdomen,^{3,6,18,19} but when put to the test the performance of CT-abdomen in patient series in the literature is more disappointing. For example, hypoperfusion is considered a pathognomonic sign for small bowel ischemia, but it was only seen in a third of patients found to have ischemic bowel at laparotomy.⁶ Furthermore, CT-features are not specific enough to distinguish safely between a single or a strangulated/loop adhesion.²⁰ The accuracy and interobserver agreement for the “whirl sign” as an indicator of small bowel volvulus are poor²¹ and the identification of a transition zone on CT-abdomen is not found to be predictive of the need for surgery.⁸

Despite its shortcomings, the CT-abdomen is readily available in most clinics and unlike the small bowel follow-through or video capsule it does not require a functioning small bowel.

We acknowledge that our series is a retrospective study and could well be subject to unforeseen bias. This is only the 2nd series clearly focusing on the distribution of causes of SBO in virgin abdomen and will require confirmation from other centers. Since SBO caused by an incarcerated external hernia should reveal itself on physical examination and as such does not pose a diagnostic dilemma,¹ we deliberately chose not to include this form of SBO in our study.

Conclusions

In patients with a virgin abdomen presenting with an SBO, adhesions are the most likely cause in the absence of an underlying disease. The prevalence of adhesions and the smaller incidence of an underlying malignancy in our patients are in line with reports in literature of causes of SBO in patients with previous surgery. We therefore propose that patients with a virgin abdomen could be treated as any other SBO and that laparotomy is not mandatory in this patient group. As with any SBO, a laparotomy remains indicated in a nonresolving obstruction or when bowel ischemia is suspected.

Despite the low accuracy of CT-abdomen, it might be used to try to determine the underlying cause or confirm a known disease as cause of obstruction. The result of the CT-abdomen has, however, to be taken with caution.

References

- Zielinski MD, Bannon MP. Current management of small bowel obstruction. *Adv Surg* 2011;45:1–29.
- Miller G, Boman J, Shrier I, et al. Etiology of small bowel obstruction. *Am J Surg* 2000;180:33–6.
- Mallo RD, Salem L, Lalani T, et al. Computed tomography diagnosis of ischemia and complete obstruction in small bowel obstruction: a systematic review. *J Gastrointest Surg* 2005;9:690–4.
- McCloy C, Brown TC, Bolton JS, et al. The etiology of intestinal obstruction in patients without prior laparotomy or hernia. *Am Surg* 1998;64:19–22.
- Hayanga AJ, Bass-Wilkins K, Bulkley GB. Current management of small-bowel obstruction. *Adv Surg* 2005;39:1–33.
- Desser TS, Gross M. Multidetector row computed tomography of small bowel obstruction. *Semin Ultrasound CT MR* 2008;29:308–21.
- Jarman BT. Small bowel imaging. *Surg Clin North Am* 2011;91:109–25.
- Colon MJ, Telem DA, Wong D, et al. The relevance of transition zones on computed tomography in the management of small bowel obstruction. *Surgery* 2010;147:373–7.
- Omori H, Asahi H, Inoue Y, et al. Etiology of intestinal obstruction in patients without a prior history of laparotomy or a detectable external hernia on physical examination. *Int Surg* 2006;91:188–93.
- Attard JA, MacLean AR. Adhesive small bowel obstruction: epidemiology, biology and prevention. *Can J Surg* 2007;50:291–300.
- Jenkins JT, Taylor AJ, Behrns KE. Secondary causes of intestinal obstruction: rigorous preoperative evaluation is required. *Am Surg* 2000;66:662–6.
- Drożdż W, Budzynski P. Change in mechanical bowel obstruction demographic and etiological patterns during the past century: observations from one health care institution. *Arch Surg* 2012;147:175–80.
- Zissin R, Hertz M, Gayer G, et al. Congenital internal hernia as a cause of small bowel obstruction: CT findings in 11 adult patients. *Br J Radiol* 2005;78:796–802.
- Habib E, Elhadad A. Small bowel obstruction by a congenital band in 16 adults. *Ann Chir* 2003;128:94–7.
- Williams SB, Greenspon J, Young HA, et al. Small bowel obstruction: conservative vs. surgical management. *Dis Colon Rectum* 2005;48:1140–6.
- Miller G, Boman J, Shrier I, et al. Small-bowel obstruction secondary to malignant disease: an 11-year audit. *Can J Surg* 2000;43:353–8.
- Idelevich E, Kashtan H, Mavor E, et al. Small bowel obstruction caused by secondary tumors. *Surg Oncol* 2006;15:29–32.
- Sailer J, Zacherl J, Schima W. CT of small bowel tumours. *Cancer Imaging* 2007;7:224–33.
- Hara AK, Leighton JA, Sharma VK, et al. Imaging of small bowel disease: comparison of capsule endoscopy, standard endoscopy, barium examination, and CT. *Radiographics* 2005;25:697–711.
- Kim JH, Ha HK, Kim JK, et al. Usefulness of known computed tomography and clinical criteria for diagnosing strangulation in small-bowel obstruction: analysis of true and false interpretation groups in computed tomography. *World J Surg* 2004;28:63–8.
- Gollub MJ, Yoon S, Smith LM, et al. Does the CT whirl sign really predict small bowel volvulus?: Experience in an oncologic population. *J Comput Assist Tomogr* 2006;30:25–32.