
PART 1

GENERAL BIOLOGY
VISCERAL ANATOMY

Gross and microscopic visceral anatomy of the male Cape fur seal *Arctocephalus pusillus pusillus* (Pinnipedia: Otariidae), with reference to organ size and growth

C. L. Stewardson, S. Hemsley, M. A. Mejer, P. J. Canfield and J. H. Maindonald

© Journal of Anatomy (Cambridge)

Published 1999, volume 195, pages 235–255.

ABSTRACT

The gross and microscopic anatomy of the Cape fur seal heart, lung, liver, spleen, stomach, intestine and kidneys ($n = 31$ seals) is described. Absolute and relative size of organs from 30 male seals are presented, with histological examination conducted on 7 animals. The relationship between log body weight, log organ weight and age was investigated using linear regression. Twenty five animals were of known age, while 6 were aged from counts of incremental lines observed in the dentine of tooth sections. For the range of ages represented in this study, body weight changes were accurately described by the exponential growth equation, $\text{weight} = w_0 r^t$, with body weight increasing by 23% per annum until at least 9–10 y of age. Organ weight increased at a rate of between 25% and 33% per annum until at least 9–10 y of age, with the exception of the intestines, where exponential increase appeared to have ceased by about 7 y. The relationship between body weight and organ weight was investigated using logarithmic transformations of the allometric equation, $y = ax^b$, where the exponent b is 1 if organ weight is proportional to body weight. Most organs increased in proportion to the body. However, the heart, liver and spleen had exponents $b > 1$, suggesting that these organs increased at a faster rate than the body. The basic anatomical features of the viscera were similar to those of other pinnipeds, with some exceptions, including the arrangement of the multilobed lung and liver. Apart from the large liver and kidneys, relative size of the organs did not differ greatly from similar sized terrestrial carnivores. The histological features of the organs were generally consistent with those previously described for this species and other otariids. The heart, as in other pinnipeds, was unlike that of cetacea in not having unusually thick endocardium or prominent Purkinje cells. Notable histological features of the lungs included prominent fibrous septa, prominent smooth muscle bundles, cartilage extending to the level of the alveolar sacs and ample lymphoid tissue. The spleen had a thick capsule, well developed trabeculae and plentiful plasma cells. Abundant parietal cells were present in the fundic glands and lymphoid follicles were present in the gastric lamina propria, particularly in the pyloric region. Small intestinal villi were very long but this could have resulted from underlying chronic inflammation. Lymphoid follicles were prominent in the colon. The kidney reniculi each had a complete cortex, medulla and calyx, but a sporta peri medullaris musculosa was not identified.

Key words: Pinnipeds, organ growth, allometry

INTRODUCTION

Little research has been carried out on the gross visceral anatomy of the Otariidae. Early descriptions have concentrated largely on the California sea lion, *Zalophus californianus*, and the South American sea lion, *Otaria byronia* (Murie, 1874; Green, 1972; Odell, 1981; Vaz-Ferreira, 1981); while histological studies have mainly concentrated on the California sea lion and the Steller sea lion, *Eumetopias jubatus* (Simpson & Gardner, 1972). Information for the southern fur seals, *Arctocephalus* spp., is scant. Apart from organ weights, no attempt has been made to describe the gross visceral anatomy of this genus. Published information on histological features of southern fur seals is limited to a study of the kidneys of 6 Cape fur seals, *Arctocephalus pusillus pusillus* (Bester, 1975), the lung of 1 Cape fur seal (Denison & Kooyman, 1973), and the spleen of 1 Antarctic fur seal, *Arctocephalus gazella* (Schumacher & Welsch, 1987).

Information on size and relative weights of the viscera has been published for several species of otariids, including the California sea lion (Forbes, 1882), Steller sea lion (Engle, 1926), northern fur seal, *Callorhinus ursinus* (Scheffer, 1960), New Zealand sea lion, *Phocarcos hookeri* (King, 1983), New Zealand fur seal, *Arctocephalus forsteri* (Miller, 1975), subantarctic fur seal, *Arctocephalus tropicalis* (Bonner, 1968), and the Antarctic fur seal (Bonner, 1968; Payne, 1979). However, most of these records are incomplete. Apart from studies conducted by Bryden (1972) and Payne (1979), few organ types have been examined and very little is known of the relative weights of organs at different age groups.

In this paper, we describe the gross and microscopic anatomy of the male Cape fur seal heart, lung, liver, spleen, stomach, intestine and kidneys. Absolute and relative size of organs from 30 seals are presented, with histological examination conducted on 7 animals ($n = 31$ seals). The relationship between log body weight, log organ weight and age was investigated using linear regression.

MATERIALS AND METHODS

Animals

The Cape fur seal breeds at 25 colonies distributed from Black Rocks (lat. 33° 50'S, long. 26°15'E) on the south-east coast of South Africa, to Cape Cross (lat. 21° 46'S, long. 13° 57'E), Namibia. Males are weaned at 6 to 12 months of age (Warneke & Shaughnessy, 1985; David, 1987), attain puberty between 3 and 4 y of age (Stewardson *et al.*, 1998) and are able to hold territories when aged *c.* 10–14 y of age (David, 1989). They are considerably larger than females and attain an average length and weight of 217 cm and 174 kg respectively (Warneke & Shaughnessy, 1985). Estimated longevity is at least 20 y (Wickens, 1993).

Thirty-one Cape fur seals were included in this study (Table 2.1). These animals were inadvertently

drowned within trawl nets during commercial fishing operations off the coast of southern Africa. Exceptions included 1 juvenile that died of head injuries (PEM2198), and a 2nd juvenile collected under scientific permit (AP5162). Animals were collected in the area 32°–36°S and 17°–24°E, between June 1986 and May 1998. Twenty five seals were of known-age, while 6 were aged from incremental lines observed in the dentine of tooth sections. Organ weights were taken from every animal, except AP5162. Seven of these animals were immediately placed on ice and brought back to a laboratory within 36 h of death for dissection and histological fixation: 2 juveniles (AP5162; PEM2198), 2 subadult (PEM 2257a; PEM2253) and 3 adult seals (PEM2400; PEM 2257b; PEM2348). PEM2198 was frozen prior to dissection.

Morphometry

Standard necropsies were performed and biological parameters recorded, based on recommendations of the Committee on Marine Mammals, American Society of Mammalogists (1967). Standard body length was measured in a straight line from the tip of the snout to the tip of the tail, with the unskinned animal lying on its back. Blubber measurements were taken at the base of the sternum. Upper canines were collected for age determination. Body organs, including the heart, lung, liver, spleen, stomach, intestine and kidneys, were excised and examined directly. Before the organs were weighed, blood was removed from the heart and the stomach washed. The intestine was separated from the mesentery, laid out horizontally, and total length measured. The intestines were weighed full. Lung weights included the trachea and bronchi. Organs were weighed using a beam or electronic balance, and measurements were taken to the nearest 5 mm using a flexible tape measure or vernier callipers as appropriate.

The relationship between body weight and organ weight was investigated using the logarithmic (base *e*) transformation of the allometric equation, $y = ax^b$, where y = organ weight (g); x = body weight (kg); a = proportionality coefficient ($y = a$ when $x = 1$); exponent = b (Schmidt-Nielsen, 1984). The equation may equivalently be written:

$$\log y = \log a + b \log x \\ = a' + b \log x$$

and this form can be fitted using straight line regression, where now b can be estimated as the slope of the regression line. We have used 'robust' variant of straight line regression, implemented in S-PLUS (Chambers & Hastie, 1991). This gives a reduced weight to data points which lie well away from the line.

The relationship between body weight and age (y) was investigated using the exponential growth equation, weight = $w_0 r^t$, where w_0 = weight at time zero;

Table 2.1 Details of 31 male Cape fur seals caught off the coast of southern Africa

Accession no. ^a	Date	Age ^b	SBL ^c (cm)	Weight (kg)	Girth (cm)	Blubber ^d (cm)
AP5162	21 May 98	6mo	90	16	64	—
AP5001	1 Oct 96	10 mo	96	24	75	2.7
AP5000	1 Oct 96	10 mo	96	22	67	2.3
AP4998	7 Oct 96	10 mo	93	18	61	2.0
PEM2198	6 July 94	1 y	104	28	67	—
AP5134	22 May 97	1 y 6 mo	97	24	66	2.3
AP4985	26 June 96	1 y 7 mo	92	19	59	1.5
AP5005	18 Oct 96	1 y 11 mo	91	18	57	1.0
AP4023	28 June 89	2 y 7 mo	113	34	75	1.3
AP4991	15 Aug 96	2 y 9 mo	102	29	67	1.0
AP5142	19 Aug 97	2 y 9 mo	107	28	72	2.0
AP5135	23 July 97	3 y 8 mo	110	36	78	1.7
AP4996	28 Sep 96	3 y 10 mo	115	30	70	1.7
AP5002	6 Oct 96	3 y 10 mo	108	33	72	1.8
AP4584	19 Jan 95	4 y 2 mo	125	42	81	2.3
AP4585	19 Jan 95	4 y 2 mo	152	38	79	1.3
AP5022	26 Nov 96	5 y	139	55	85	1.2
AP4595	17 Oct 95	4 y 11 mo	134	51	87	1.4
AP3582	6 June 86	5 y 6 mo	142	58	90	3.0
AP3589	12 Aug 86	5 y 8 mo	148	68	98	2.3
AP4987	5 Aug 96	5 y 8 mo	144	54	88	1.7
PEM2257a	19 Sep 94	6 y	142	73	93	1.7
AP5021	26 Dec 96	6 y 1 mo	141	55	90	0.9
AP5133	14 Jan 97	6 y 1 mo	153	69	88	0.8
AP5136	15 July 97	6 y 8 mo	149	74	98	2.3
PEM2253	27 Aug 94	7 y	152	86	128	4.0
PEM2400	13 July 95	8 y	176	97	102	2.9
AP4597	15 Sep 95	8 y 10 mo	170	101	109	2.4
PEM2257b	7 Oct 94	9 y	170	128	120	4.0
AP4992	13 Sep 96	9 y 10 mo	165	95	107	2.3
PEM2348	14 Nov 94	10 y	189	179	97	3.3

^a AP, Sea Fisheries Research Institute, seal accession number; PEM, Port Elizabeth Museum, seal accession number.

^b Age in months and years.

^c Standard body length, i.e., straight line from the tip of the snout to the tip of the tail, with the unskinned animal lying on its back.

^d Blubber thickness taken at the base of the sternum. Bold, seals examined histologically ($n = 7$).

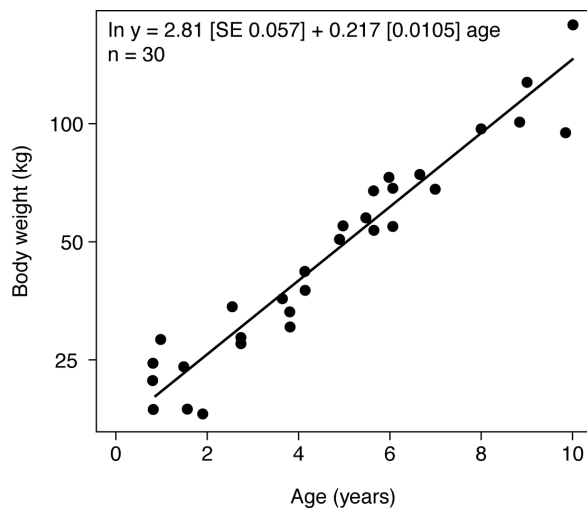


Fig. 2.1 The relationship between log body weight (kg) and age (y) in the male Cape fur seal.

r = the factor by which body weight is multiplied for each additional year of age, and t = time in y. The equation may equivalently be written:

$$\begin{aligned} \log(\text{weight}) &= \log(w_0) + t \log r \\ \text{weight} &= a_0 + ct \end{aligned}$$

where $a_0 = \log(w_0)$ and $c = \log r$. The same equation was used to determine the relationship between organ weight and age (y).

Histology

Sections of the heart, lung, liver, spleen, stomach, intestine and kidneys were fixed in 10% phosphate buffered formalin for a minimum of 24 h before being stored in 70% alcohol prior to routine processing for histological analysis (Drury & Wallington, 1967). Sections of wax embedded tissues (5–10 μm) were stained with haematoxylin and eosin. Tissues showed variable degrees of autolysis. Where appropriate, this has been mentioned in the results for specific organs.

Table 2.2 Mean by age class of relative weights of the heart, lung, liver, spleen, stomach, intestine and kidneys in the male Cape fur seal

Age (y)	No. ^a	Body weight ^b (kg)	Heart	Lung	Liver	Spleen	Stomach	Intestine	Kidneys
1	4	23	0.5	2.1 (3)	2.6	0.1	1.0	3.6 (3)	0.6
2	3	20	0.6	2.7	3.8	0.2	1.6	5.0	1.0
3	3	30	0.5	2.3	3.3	0.2	1.4	5.2	0.8
4	5	36	0.5	2.8	3.6	0.2	1.3	4.8	0.8
5	2	53	0.5	2.6	4.1	0.2	1.7	5.3	0.8
6	6	62	0.6	2.7 (5)	4.5	0.3	1.5	4.6 (5)	0.8
7	2	71	0.6	2.0 (1)	4.3	0.2	1.6	4.6 (1)	0.8
8	1	97	0.7	–	4.4	0.2	1.6	–	0.8
9	2	115	0.6	2.7 (1)	3.8	0.3	1.3	3.5 (1)	0.8
10	2	137	0.6	2.5 (1)	4.3	0.4 (1)	1.4	3.8 (1)	0.8
Mean			0.5	2.5	3.8	0.2	1.4	4.5	0.8
Total	30	30	30	24	30	29	30	24	30

Organ sample size is given in brackets where this does not equal total sample size.

^a Total number of seals.

^b Mean body weight.

Age determination

The age of animals was estimated from counts of incremental lines observed in the dentine of tooth sections. Upper canines were sectioned longitudinally using a circular diamond saw. Sections were ground down to 280–320 µm, dehydrated, embedded in resin and viewed under a stereomicroscope in polarised light (Oosthuizen, 1997). Each section was counted 5 times by an individual reader and ages were rounded off to the nearest birth date. The median date of birth was assumed to be 1 December (Shaughnessy & Best, unpublished report). For the purpose of this study the following age classes were used: juvenile (< 1 y and 6 mo); 2-y-old; subadult (3–7 y); adult (≥ 8 y of age).

RESULTS

Details of the 31 male specimens are presented in Table 2.1. They ranged from 6 mo to 10 y of age. Body lengths varied between 90 and 189 cm, and body weights between 16 and 179 kg. All animals were in good physical condition as inferred from blubber thickness, i.e., blubber thickness ranged from 2.0–2.7 cm in juveniles and up to 4.0 cm in adults.

Body weight and age

The relationship between body weight and age (y) is presented in Fig. 2.1. The fitted line represents the exponential growth equation, $\text{weight} = w_0 r^t$, with body weight on the log transformed vertical axis and t (time in y) on the horizontal axis. For the range of ages represented in this study, data are consistent with a constant relative increase of 23% per y until at least 9–10 y of age.

Organ size

Mean body weights, and mean relative organ weights, by age class are presented in Table 2.2.

Organ growth

The relationship between organ weight, body weight and age is presented in Fig. 2.2a, b. In Fig. 2.2a the fitted line represents the allometric equation, $y = ax^b$, with organ weight on the log transformed vertical axis, and body weight on the log transformed horizontal axis. When data on seals of all age classes are considered, exponents b (the slope of the line) for the lungs, stomach, intestine and kidneys were not significantly different from 1, suggesting that these organs increased in weight in proportion to the body weight. However, the heart, liver and spleen had exponents $b > 1$, suggesting that these organs increased at a faster rate than the body (Table 2.3).

In Fig. 2.2b the fitted line represents the exponential growth equation, $\text{weight} = w_0 r^t$, with organ weight on the log transformed vertical axis and t (time in y) on the horizontal axis. Organ weight increased at a rate of between 25% and 33% per year until at least 9–10 y of age (Table 2.3).

Gross and microscopic anatomy

Heart

The heart was positioned obliquely within the thoracic cavity, slightly to the left, between the 3rd and the 7th rib (Fig. 2.3). The heart was flat and broad, with a slight bifurcation at its apex (Fig. 2.4). Partially covered by the surrounding lungs, it was enclosed in a pericardium and attached at the apex to the diaphragm. It possessed the typical mammalian

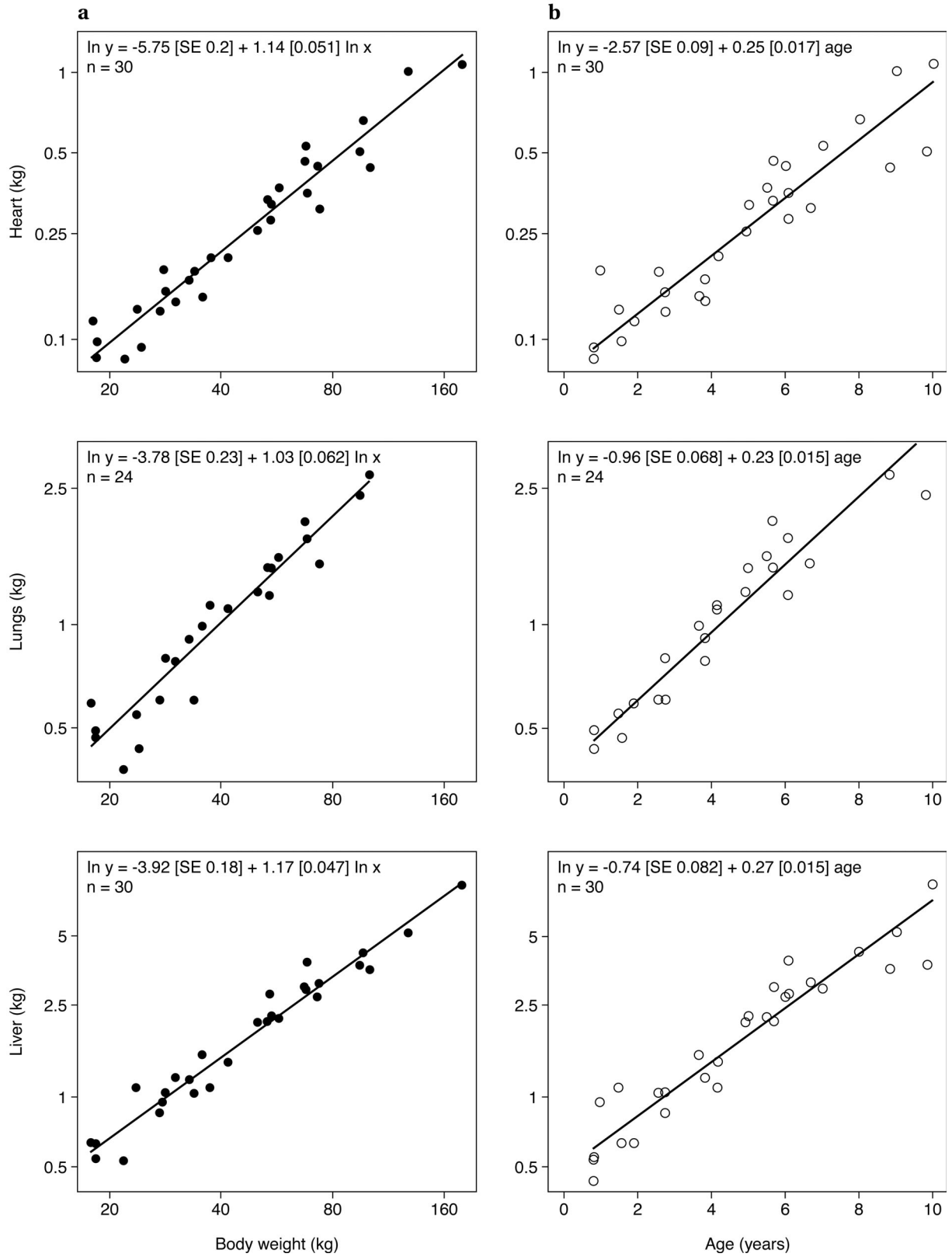


Fig. 2.2 For legend see page 25.

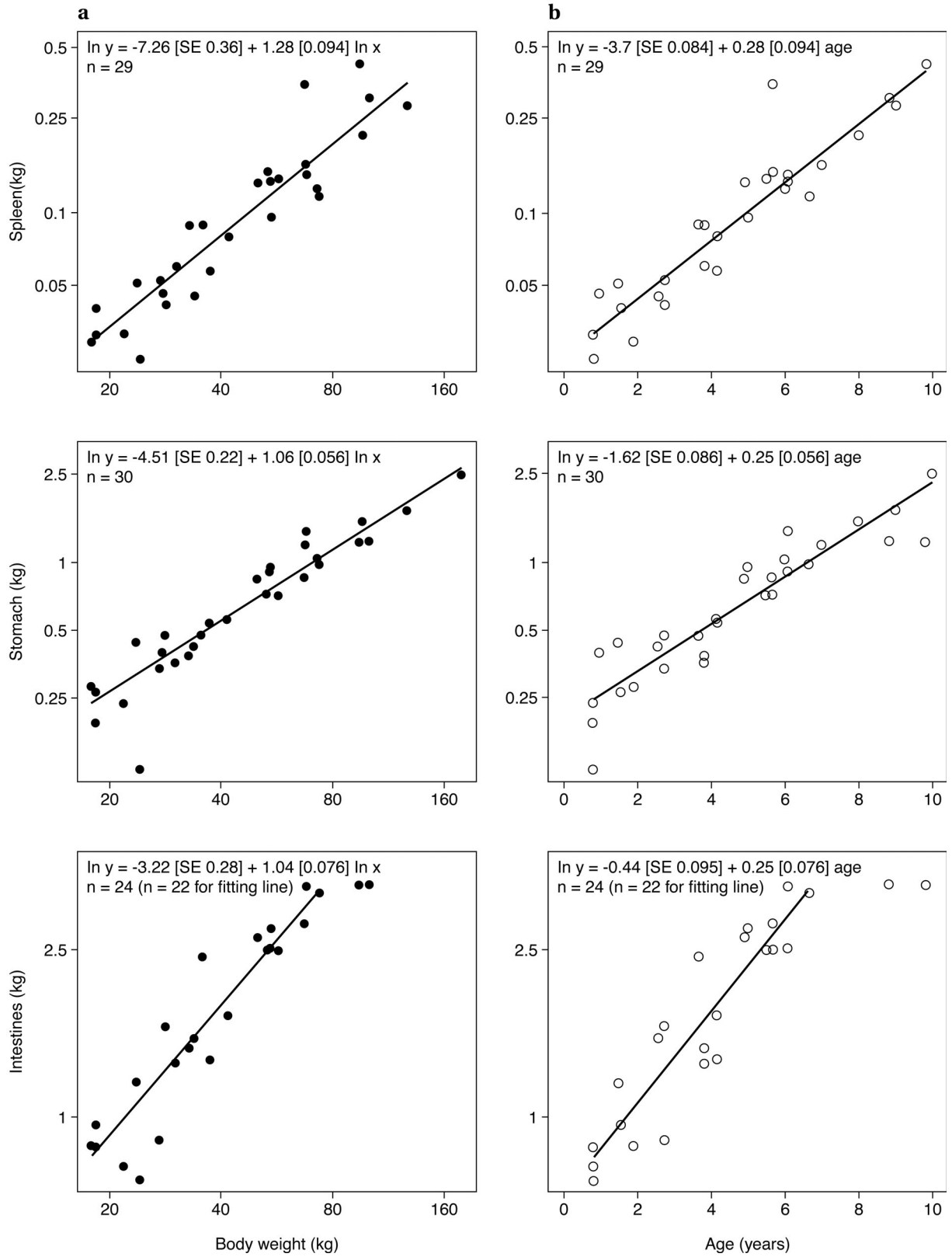


Fig. 2.2 For legend see page 25.

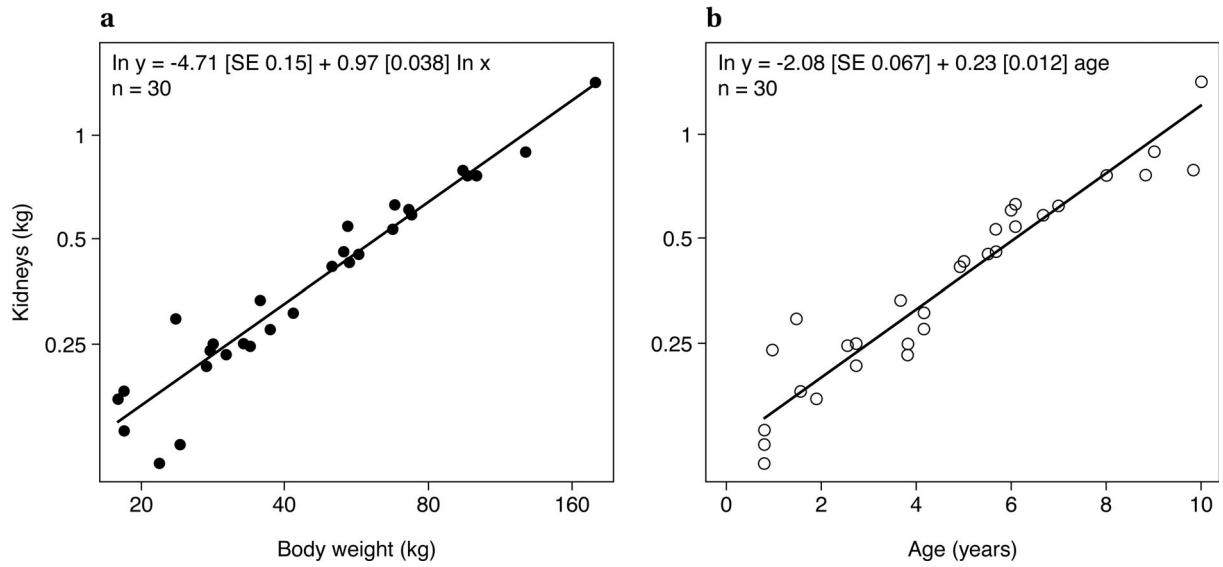


Fig. 2.2 The relationship between (a) log organ weight and log body weight ($y = ax^b$), and (b) log organ weight and age (weight = $w_0 r^t$) in the male Cape fur seal.

Organ sample size: heart, 30; lung, 24; liver, 30; spleen, 29; stomach, 30; intestine, 24; kidneys, 30.

Exponent b , slope of the regression line; S.E. [b], standard error of b .

Note: the unusually large spleen found in a 6 y-old animal (AP3589), which the robust fitting routine has effectively excluded in fitting the line. For intestines, where exponential increase appears to have ceased by c. 7 y, we used only seals less than 7 y in fitting the line.

Table 2.3 Organ weight in relation to body weight and age in the male Cape fur seal

	Exponent b^a	S.E. [b]	D.F.	P	c^b	S.E. [c]	increase per y (%)
Whole body	–	–	28	–	0.22	0.011	23
Heart	1.14	0.05	28	0.01	0.25	0.017	28
Lung	1.03	0.06	22	NS	0.23	0.015	26
Liver	1.17	0.05	28	0.001	0.27	0.015	31
Spleen	1.28	0.09	27	0.005	0.28	0.016	33
Stomach	1.06	0.06	28	NS	0.25	0.016	28
Intestine	1.04	0.08	20	NS	0.25	0.023	29
Kidneys	0.97	0.04	28	NS	0.23	0.012	25

Estimation of b and c values for the allometric equation $y = ax^b$, and the exponential growth equation weight = $w_0 r^t$.

^a b is the exponent in $y = ax^b$.

^b c is $\log r$, where r is the factor by which the organ weight is multiplied for each additional year of age in the exponential growth equation, weight = $w_0 r^t$.

NS, not significant at the 0.05 level for a test that $b = 1$.

arrangement of 4 chambers separated by aortic, pulmonary, left and right atrioventricular valves (Evans, 1993). The arrangement of the arteries was most similar to that found in *Neophoca* spp. (King, 1983, p. 179). The ascending aorta enlarged at the level of the brachiocephalic artery to form an aortic bulb.

Samples of left and right ventricles, left atrium, aortic arch, pulmonary trunk, pulmonary artery and aortic valve from 3 seals; right atrium from 2 seals, and right pulmonary valve from 1 seal were examined histologically. All animals were adult.

The cardiac tissue had usual mammalian features. The epicardium consisted of mesothelium overlying prominent connective tissue and was associated with variable adipose tissue. Connective tissue trabeculae containing blood vessels penetrated the myocardium. The endocardium was thicker in the ventral left ventricle than at the other sites examined but overall the endothelium did not appear unusually thick. The appearance of the myocardial cells was unremarkable and Purkinje cells were difficult to distinguish morphologically from other myocardial cells.

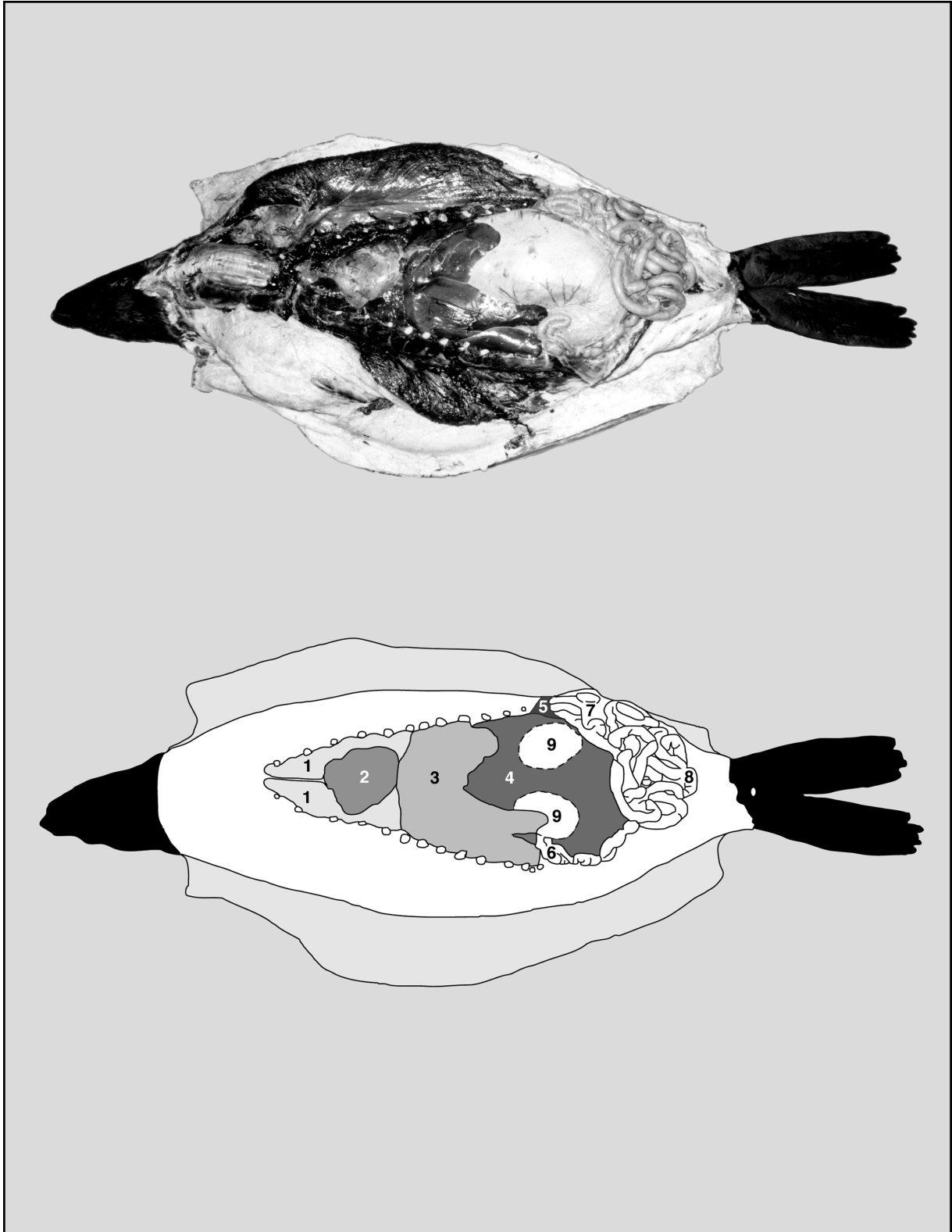


Fig. 2.3 Orientation of the major organs within the thoracic cavity of a 9 y-old (adult) Cape fur seal, ventral aspect. 1, lung; 2, heart; 3, liver; 4, stomach; 5, spleen; 6, duodenum; 7, small intestine; 8, large intestine; 9, kidneys (dorsal to the stomach).

The pulmonary and aortic valves consisted of dense connective tissue with some apparent elastic fibres, and had endocardium on both sides. The aortic valve had prominent layers of probable elastic fibres at its base. The aorta was a typical thick-walled, elastic artery with a thick adventitia. The pulmonary artery was a muscular artery with prominent endothelial cells.

Lungs

The trachea and bronchi of the mature Cape fur seal (e.g., AP4992) were supported dorsoventrally by incomplete cartilaginous rings. Within this distinct dorsal gap, the oesophagus was attached within connective tissue. Bifurcation of the trachea into 2 main stem bronchi occurred *c.* 13 cm caudal to the larynx. The main stem bronchi ran parallel until they diverged at a 2nd bifurcation *c.* 30 cm caudal to the larynx.

The distinct dorsal gap observed in the adult bronchi was absent in the juvenile (e.g., AP5162). Instead, the cartilaginous rings overlapped dorsally. The bronchi entered the lungs at the same level as the pulmonary vein. Bifurcation occurred *c.* 10 cm caudal to the larynx.

The position of the lungs and heart within the thorax is illustrated in Fig. 2.3. The lungs were multilobed with deep fissures between each lobe (Figs. 2.5, 2.6). The right lung consisted of cranial, middle, caudal and accessory lobes. The right cranial lobe was broadly triangular, whereas the right middle lobe was smaller and elongated. The right caudal lobe was triangular, and had a cone-shaped, partially ridged accessory lobe extending from its ventral surface. The middle and caudal lobes were attached to one another along 10% of their borders, while 1/3rd of the accessory lobe was attached to the caudal lobe.

The left lung consisted of a divided cranial lobe and an undivided caudal lobe. The left caudal lobe was triangular in shape. The left cranial lobe consisted of 2 distinct divisions that were attached to one another along *c.* 40% of their borders by connective tissue.

Lung samples taken from multiple sites were obtained from 2 adult seals and examined in more detail histologically. One seal had a group of nematodes present in the lung and limited areas of focal pneumonia. These areas were not included in the following description. The lungs of both seals showed congestion, oedema and collapse of smaller airways, consistent with lung compression. Pulmonary oedema, although a nonspecific change, may have been due to drowning (Cooke, 1993).

The pleura was thick and consisted of 3 layers (Fig. 2.7). Beneath the outer mesothelial layer was a thin layer of probable elastic tissue, beneath which was a thick layer of loose connective tissue containing blood vessels, lymphatic vessels and some nerves. Fibrous septa extending from the pleura were very prominent.

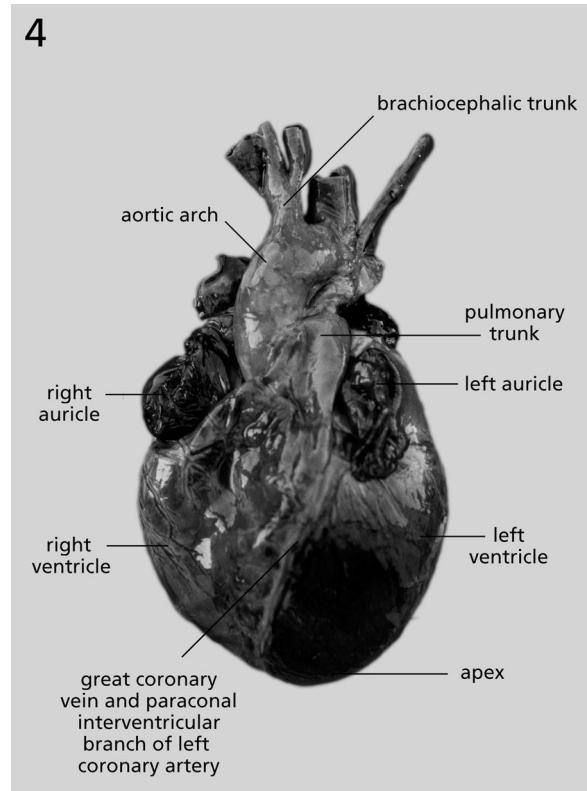


Fig. 2.4 Heart of a Cape fur seal, dorsoventral.

Larger airways, including the primary bronchus, had folded epithelium, presumably due to airway collapse. The pseudostratified columnar epithelium was underlain by a prominent layer of acellular, dense connective tissue. Beneath this layer was vascular connective tissue surrounded by an incomplete layer of smooth muscle. External to this muscular tissue was connective tissue interspersed with mucous glands and blood vessels. Cartilage plates surrounded this connective tissue layer and external to the cartilage were some mucous glands and a surrounding thin layer of connective tissue. Mucous glands were absent from smaller airways. Goblet cells were numerous in the epithelium, especially in larger airways. Histological features of a large intrapulmonary airway are shown in Fig. 2.8.

The height of the epithelium was decreased in smaller airways, eventually becoming low columnar to cuboidal, and the surrounding layers were less well developed. Cartilage was present in even very small airways, including airways with simple cuboidal epithelium from which alveoli originated. A complete smooth muscle layer was present in smaller airways, and isolated smooth muscle bundles were observed in alveolar septa (Fig. 2.9). Lymphoid aggregates, scattered lymphocytes and plasma cells were commonly present in the lamina propria and submucosa of airways.

Examination of a single section of trachea revealed histological features similar to those of large intrapulmonary airways. Adipose tissue, muscle and blood vessels were found external to the tracheal cartilage.

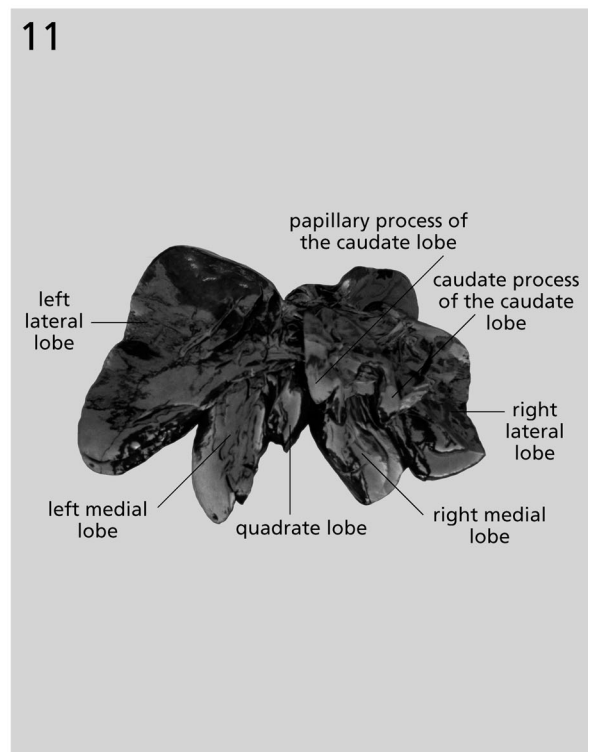
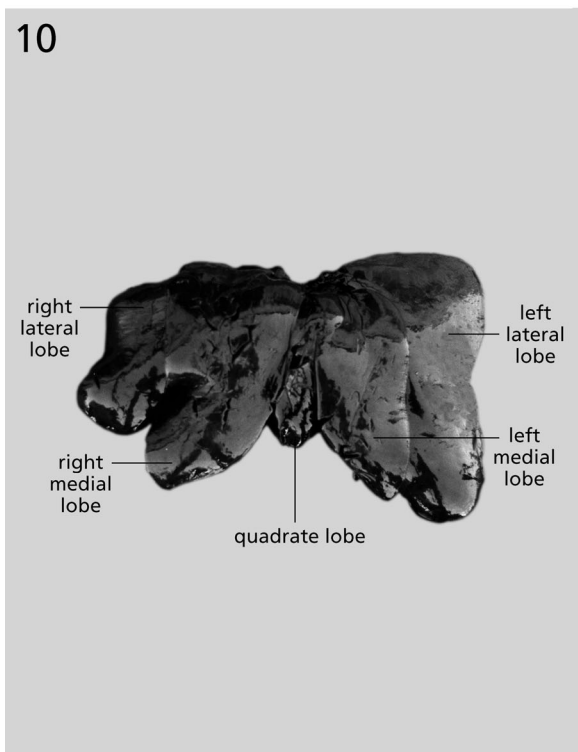
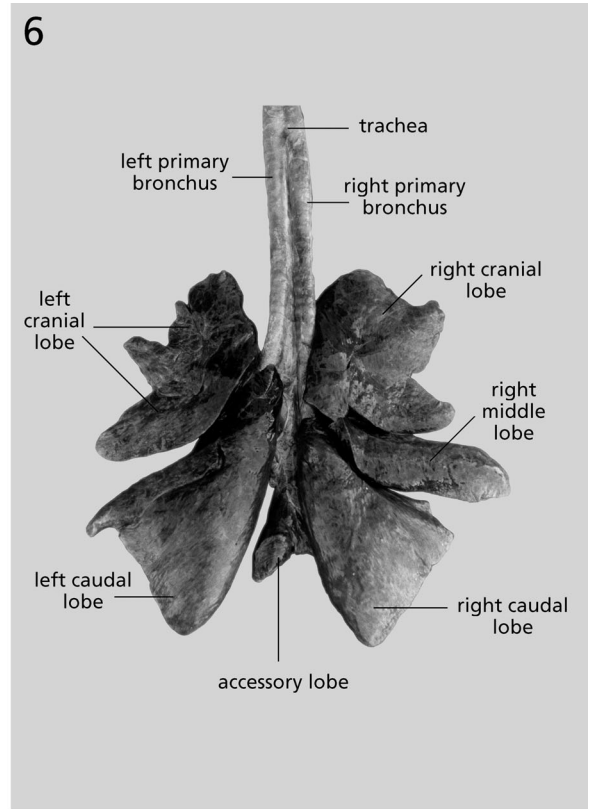
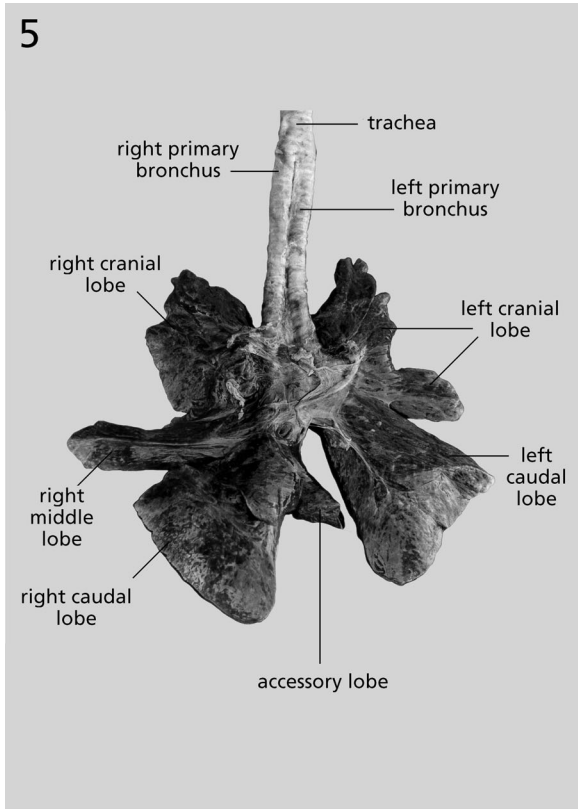


Fig. 2.5 Lung of a Cape fur seal, ventral aspect.

Fig. 2.6 Lung of a Cape fur seal, dorsal aspect.

Fig. 2.10 Liver of a Cape fur seal, diaphragmatic aspect.

Fig. 2.11 Liver of a Cape fur seal, visceral aspect.

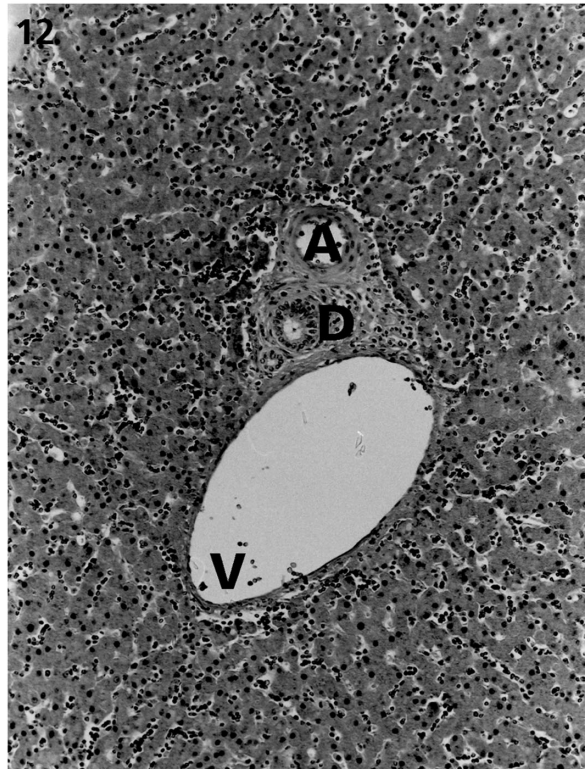
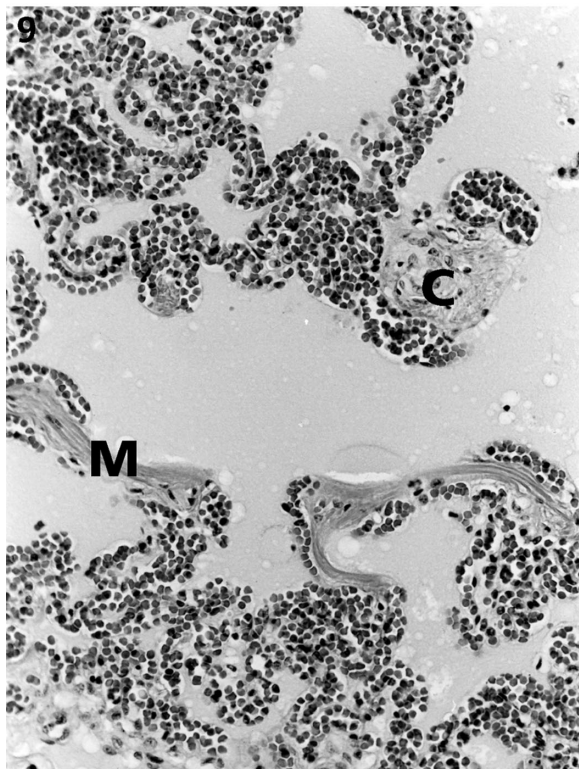
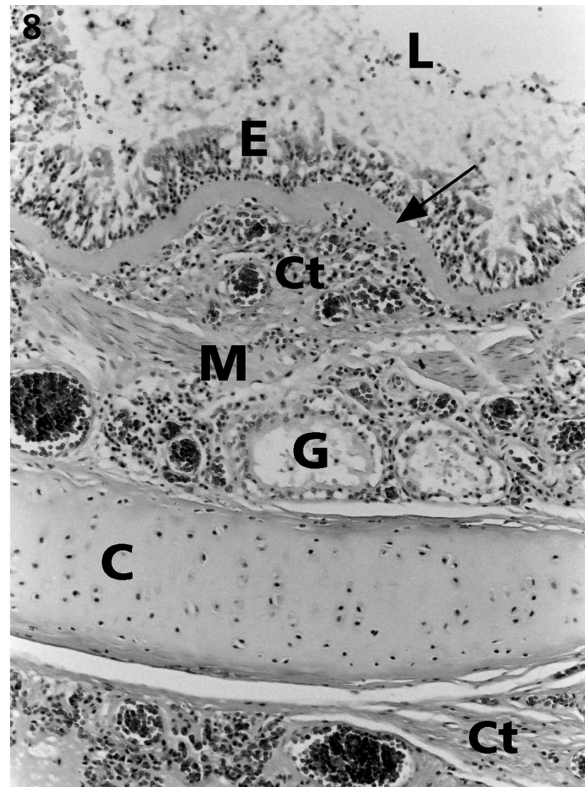
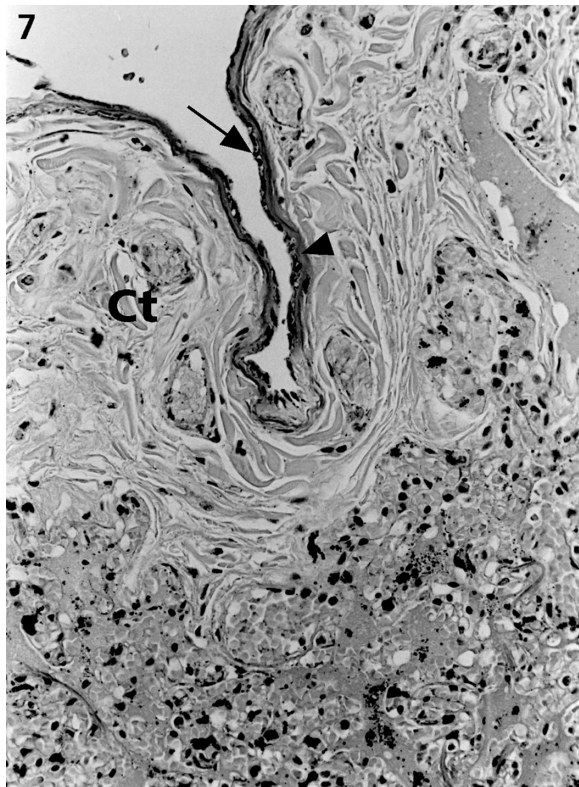


Fig. 2.7 Pulmonary pleura of a Cape fur seal demonstrating the presence of an outer mesothelial layer (arrow), an underlying layer of probable elastic tissue (arrow head) and a deep layer of loose connective tissue (Ct). H & E, $\times 180$.

Fig. 2.8 Components of the wall of a large intrapulmonary airway of a Cape fur seal. The epithelium (E) is underlain by a layer of acellular, dense connective tissue (arrow) that overlies vascular loose connective tissue (Ct). Deep to this connective tissue, an incomplete layer of smooth muscle (M) overlies vascular connective tissue that contains mucous glands (G). Cartilage plates (C) surrounded by loose connective tissue (Ct) comprise the outermost components of the wall. Epithelial disruption and the presence of debris in the lumen (L) may be due to post mortem tissue deterioration or could have resulted from drowning. H & E, $\times 35$.

Fig. 2.9 Lungs of a Cape fur seal demonstrating the presence of cartilage (C) in the wall of a very small airway and smooth muscle (M) in the alveolar septa. Congestion and oedema are apparent. H & E, $\times 180$.

Fig. 2.12 Portal area of the liver of a Cape fur seal demonstrating the presence of a branch of the hepatic portal vein (V) and hepatic artery (A) in company with a bile ductule (D). A smooth muscle sphincter surrounding the vessels is not apparent. H & E, $\times 90$.

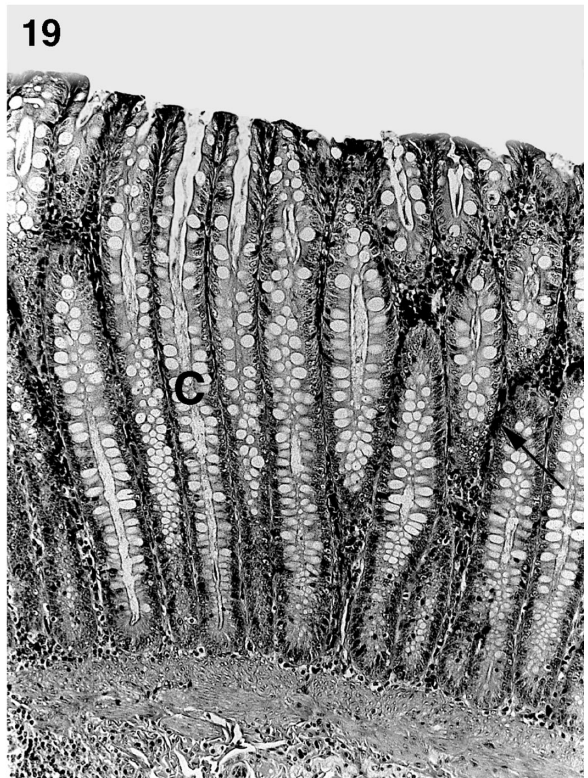
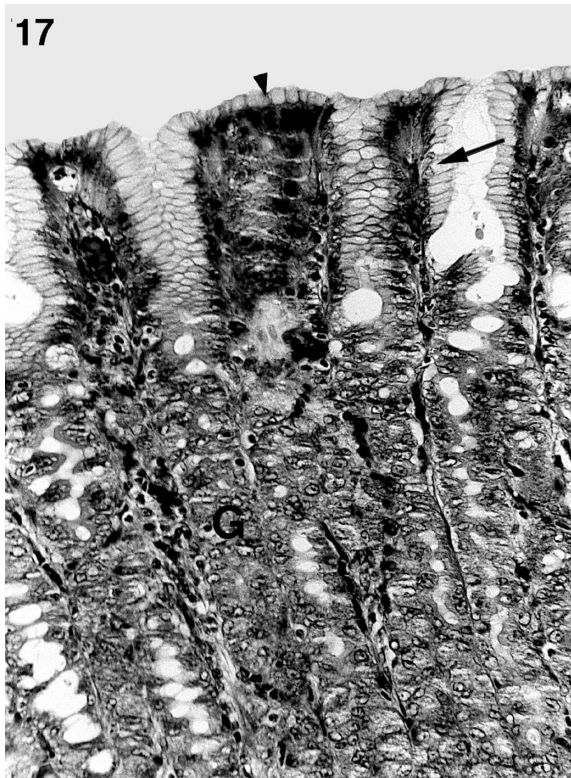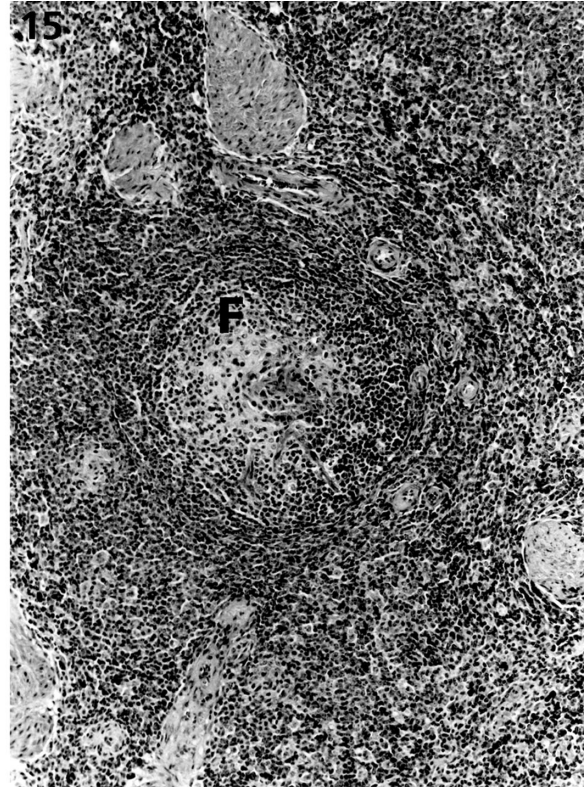
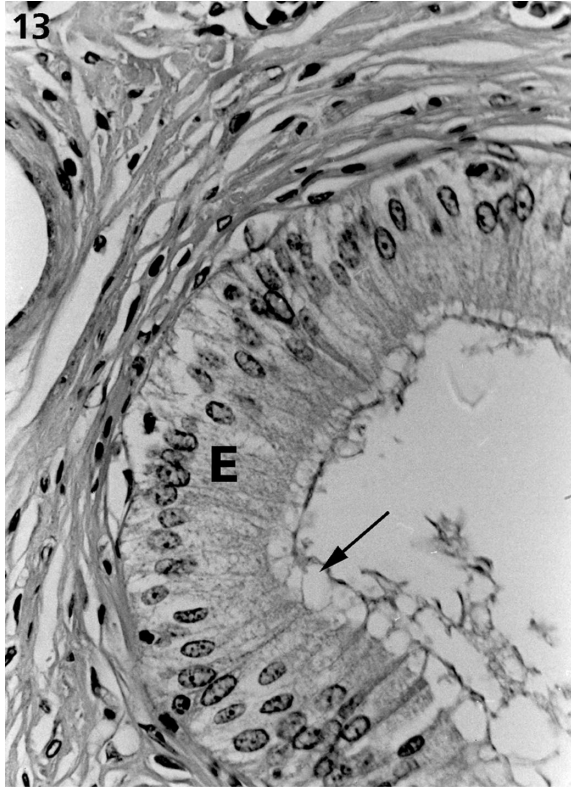


Fig. 2.13 Large intrahepatic bile duct of a Cape fur seal demonstrating tall columnar epithelium (E) with apical clear spaces probably corresponding to mucus removed in processing (arrow). H & E, $\times 350$.

Fig. 2.15 Spleen of a Cape fur seal demonstrating a lymphoid follicle (F) with prominent germinal centre. H & E, $\times 90$.

Fig. 2.17 Body of the stomach of a Cape fur seal demonstrating mucous surface cells (arrowhead), mucous neck cells (arrow) and the proximal bodies of fundic glands (G). H & E, $\times 180$.

Fig. 2.19 Colon of a Cape fur seal demonstrating the presence of numerous straight tubular crypts (C) with abundant goblet cells. Lymphoid cells (arrow) are evident in the lamina propria. H & E, $\times 90$.

Liver

The liver was located primarily within the right side of the abdominal cavity and extended craniocaudally from the 6th sternal to the 3rd, and final, asternal rib (Fig. 2.3). The liver had 6 distinct lobes, separated by deep natural fissures (Fig. 2.10, 2.11). From the ventral aspect, the left lateral (16.9 × 11.7 cm), left medial (21.2 × 8.9 cm), right medial (21.2 × 13.0 cm) and right lateral lobes (17.2 × 8.5 cm) could be readily distinguished. The quadrate lobe (13.2 × 7.0 cm) was located between left and right medial lobes. On the visceral aspect of the right lateral lobe was the caudate lobe, which had a caudate process (6.9 × 6.5 cm) and a papillary process (4.8 × 6.5 cm). Measurements were taken from PEM2198 (juvenile).

The piriform gall bladder was *c.* 6.5 cm long and 3.0 cm wide at its greatest diameter. It was located at the ventral surface of the right medial lobe, to the right of the ligamentum teres. The bile duct entered the proximal duodenum at the same level as the pancreatic duct.

Liver samples from 2 adult seals were examined in more detail histologically. Both livers had widespread areas of focal necrosis and leukocyte infiltration, and 1 had microabscessation. In 1 seal, hepatocellular vacuolation was common and in the other, perivascular connective tissue and lymphoid infiltration were widespread.

On examining relatively normal areas, the liver was found to have usual mammalian features. It was surrounded by a connective tissue capsule and hepatocytes were arranged in laminae of single sheets of cells. Portal areas were readily discernible but no obvious smooth muscle sphincter around vessels was seen (Fig. 2.12). Interlobular connective tissue was not prominent. Small bile ducts had cuboidal epithelium while ducts of larger diameter had more columnar epithelium, with probable apical mucus (Fig. 2.13). Gold brown pigment granules were present within many hepatocytes of 1 seal but were not obvious in the liver of the other animal. Kupffer cells were not prominent.

Spleen

The spleen was loosely attached to the greater curvature of the stomach by the gastrosplenic ligament (Fig. 2.3). This flat, elongated rectangular organ was *c.* 33 cm long and 8 cm wide at the broadest part in adults (*n* = 3 seals). The cranial extremity was generally rounded and the caudal extremity tapered (Fig. 2.14). Dark red pigmentation could be seen scattered throughout the spleen. No accessory spleens were observed.

Splenic tissue from 5 adult seals was examined histologically. Features were typically mammalian. The capsule was thick and trabeculae were very prominent. Large trabeculae contained arteries, veins and nerves. The parenchyma consisted of white and red pulp but the degree of development of lymphoid tissue was variable among individuals. Lymphoid tissue consisted

of periarteriolar lymphoid sheaths (PALS) and follicles but follicles generally predominated over PALS (Fig. 2.15). Most follicles had germinal centres, some of which showed hyaline deposits. Plasma cells were very numerous throughout the red and white pulp and occasional plasma cells were binucleate. Sheathed capillaries were not prominent. Gold brown pigment granules were present in macrophages scattered throughout the spleen. No megakaryocytes or haematopoietic islands were evident in the red pulp.

Stomach

The stomach was single chambered and J-shaped. The cardia and fundus were not well developed, therefore the region between the end of the oesophagus and the angular notch will be referred to as the body. The distal 3rd of the stomach, the pyloric portion, was directed cranially from the angular notch and narrowed into a small ostium (Fig. 2.16). The pyloric sphincter was well developed. Rugae lined the body of the stomach, whereas the pyloric portion was comparatively smooth.

The body of the stomach was located within the left side of the abdominal cavity, and the pyloric portion within the right (Fig. 2.3). When distended, the body of the stomach extended caudoventrally as far as the pelvis. The stomach was intimately associated with the liver, spleen and intestine.

Tissue samples taken from the body and pyloric regions of the stomach of 3 seals were examined histologically. Tissues from 2 animals showed signs of autolysis. Therefore, description of the epithelium and lamina propria of the surface mucosa was not possible in these animals. Neutrophilic debris was present within some of the pyloric glands of the 3rd seal. This animal had prominent diffuse and follicular lymphoid tissue in the lamina propria of both regions of the stomach and mild neutrophilic infiltration of the lamina propria of the pyloric region. Least affected areas were used for histological description.

The surface epithelium was simple columnar and consisted of cells with the typical appearance of gastric surface mucous cells. Gland neck cells were also columnar mucous cells (Fig. 2.17). The deeper parts of the glands in the body region had the typical appearance of fundic glands. They were simple, branched tubular glands with most epithelial cells consistent in appearance with chief cells and parietal cells. The latter were numerous. In the pyloric region, mucous glands were present. They were simple, branched tubular glands separated by a small amount of connective tissue. Primary lymphoid follicles were present in the deep lamina propria, particularly in the pyloric region, sometimes extending between layers of the muscularis mucosae. Scattered lymphoid cells were present in the connective tissue between glands. The muscularis mucosae was prominent with multiple layers. The submucosa consisted of loose vascular connective tissue which contained some bundles of nerve cells. Lymphocytes, plasma cells and neutrophils were

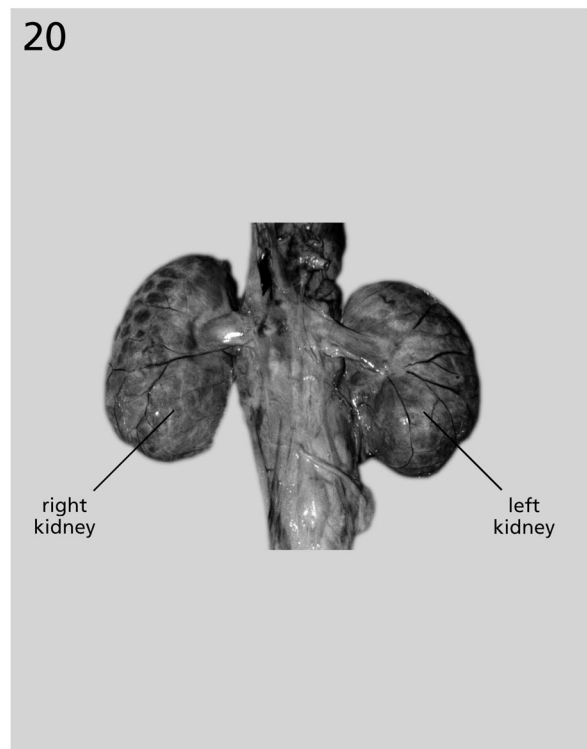
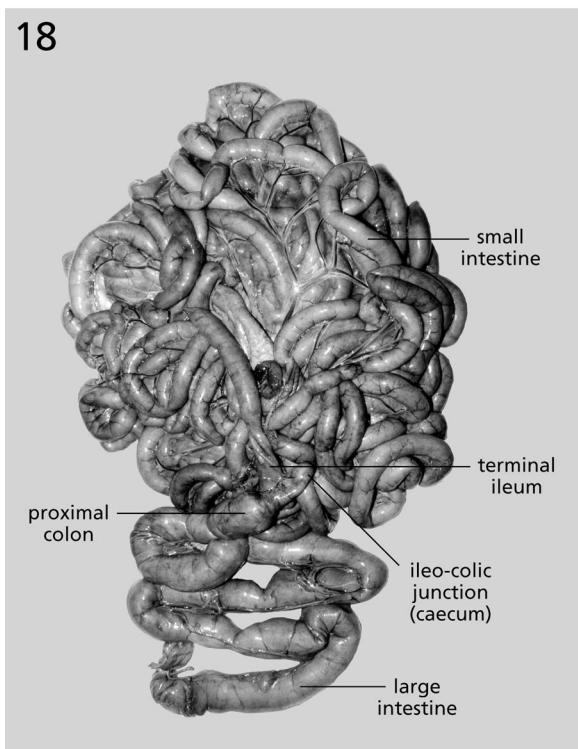
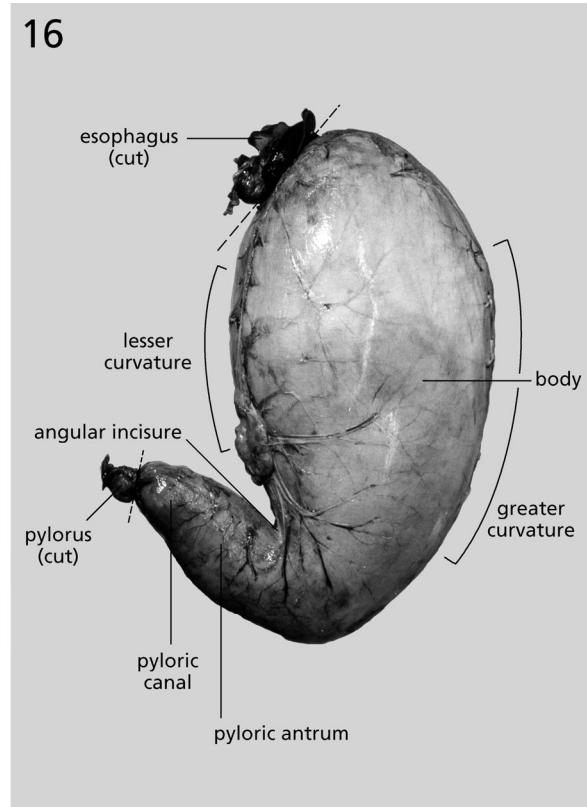


Fig. 2.14 Spleen of a Cape fur seal, parietal aspect.

Fig. 2.16 Stomach of a Cape fur seal.

Fig. 2.18 Intestine of a Cape fur seal. Note the small diverticulum at the ileo-colic junction.

Fig. 2.20 Kidneys of a Cape fur seal, ventral aspect.

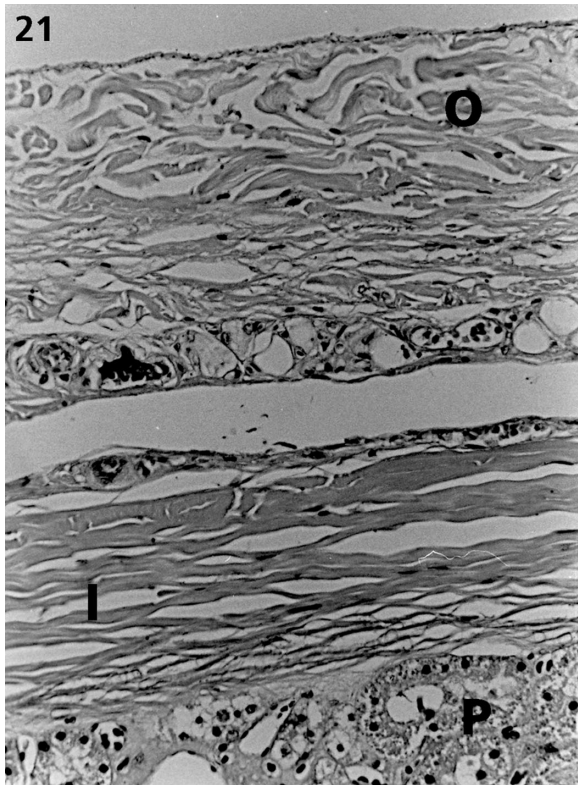


Fig. 2.21 Renal capsule of a Cape fur seal demonstrating an outer layer (O) separated from an inner layer (I) that is adherent to the parenchyma (P). H & E, $\times 180$.

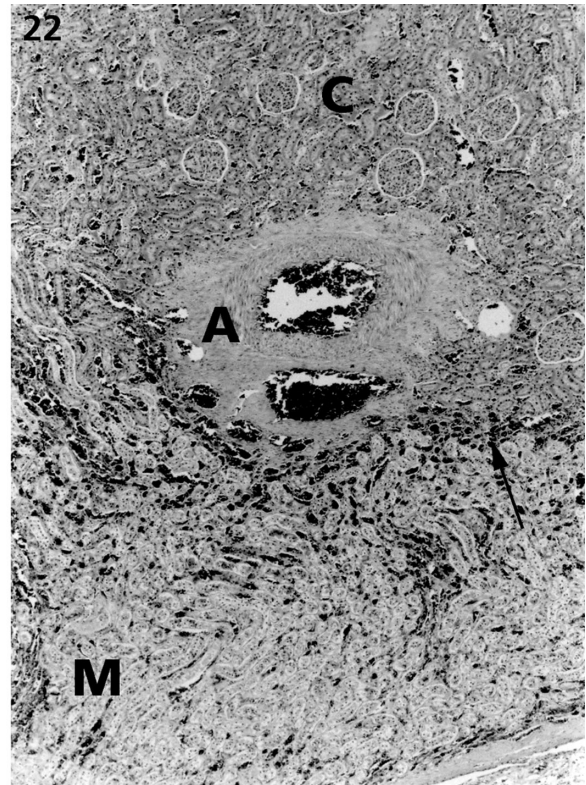


Fig. 2.22 Kidney of a Cape fur seal demonstrating the presence of muscular arteries (A) at the corticomedullary junction (arrow) but no apparent smooth muscle bundles representing a sporta peri medullaris musculosa. C, cortex; M, medulla. H & E, $\times 35$.

variably present. The tunica muscularis consisted of 2 to 3 layers which were not always readily distinguishable. The innermost layer had an oblique to circular orientation and the outermost and middle layers had an oblique to longitudinal orientation. Loose connective tissue containing vessels and bundles of nerve cells was present between the layers of the tunica muscularis.

Small and large intestine

The duodenum began at the pylorus, immediately formed a U-shaped loop to the left, passed across the ventral surface of the pylorus, and coursed caudally along the right lateral wall of the abdomen (Fig. 2.3). The duodenojejunal flexure was not distinct, thus it was difficult to distinguish grossly the duodenum from the jejunum. The jejunum formed extensive loops that were supported by well developed, fan-shaped mesentery. The ileum, which could not be distinguished grossly from the jejunum, terminated at a much reduced caecum which comprised a small diverticulum, 4.5–6.0 cm long, at the ileo-colic junction (Fig. 2.18). The large intestine was comparatively short and its luminal surface was smooth.

The small intestine was narrow and long. For example, in 1 adult seal, the dimensions were 265 cm in length and 1.7 cm in width. The large intestine was slightly wider in diameter with few flexures. Dimensions were 120 cm in length, excluding the caecum and

anal cavity, and 3.0 cm in width. The total length of the adult intestinal tract was *c.* 28 m ($n = 4$) and ranged from 25 to 32 m, 16 times the length of the body. Juvenile intestinal length was 13 m, 12 to 14 times the length of the body ($n = 2$).

Tissue samples from the jejunum and colon of 1 seal were examined histologically. The lamina propria of both regions of the intestine was moderately to heavily infiltrated with lymphoid cells and neutrophils and some crypts contained neutrophils (crypt abscesses). There were some associated areas of fibrosis in the small intestine. The least affected areas were used for histological examination.

The small intestinal villi were very long, slender and irregular in outline. The apical tips of some villi appeared to be fused. The epithelium was simple, consisting predominantly of columnar enterocytes, between which were lesser numbers of goblet cells and lymphocytes. Tubular crypts penetrated the lamina propria between the villi. The lamina propria connective tissue contained vessels, lymphoid cells and some neutrophils and eosinophils. Smooth muscle was also present in the villous cores. The muscularis mucosae was prominent and appeared to consist of 2 ill defined layers. The submucosa consisted of vascular loose connective tissue in which bundles of nerve cells could be seen. The tunica muscularis consisted of a thicker inner circular and a thinner outer longitudinal layer, between which bundles of nerve cells were evident.

The large intestine was nonvillous and had numerous straight tubular crypts penetrating the mucosa. Goblet cells were very numerous, especially in the crypts (Fig. 2.19). The surface epithelium was simple columnar. Between the crypts was sparse connective tissue with lymphoid cells and fewer numbers of neutrophils and eosinophils. The muscularis mucosae was prominent and had an inner circular layer and an outer longitudinal layer. The submucosa consisted of loose connective tissue containing bundles of nerve cells and primary lymphoid follicles. The tunica muscularis was similar in arrangement to that of the small intestine.

Kidneys

The kidneys were situated in the sublumbar region, 1 each side of the vertebral column, extending from the 2nd asternal rib to just beyond the last rib (Fig. 2.3). They were loosely attached to the abdominal muscle by connective tissue. The left kidney was slightly more caudal than the right. Each kidney was composed of numerous reniculi separated by shallow furrows and was covered by a fibrous capsule (Fig. 2.20). The average dimensions of the adult kidney were length (13.6 cm), width (7.9 cm) and height (5.9 cm) ($n = 3$). The right and left kidneys were essentially the same size and shape; a test for statistical significance of the quadratic term for kidney size having $P = 0.2$ (D.F. = 21).

Samples of renal tissue from 3 adult seals were examined in more detail histologically. The kidneys were renicular. Each single medullary papilla had an obvious inner and outer part and was enclosed by a calyx. The capsule was thick and consisted of a loose outer layer containing variable fat and vessels, and a more tightly adherent inner layer (Fig. 2.21). Extracapsular fat was present in 2 seals. Beneath the capsule, within the periphery of the cortical tissue, were numerous veins. Muscular arteries embedded in connective tissue were present at the corticomedullary junction (Fig. 2.22). While their walls appeared to contain generous amounts of smooth muscle, there were no distinct muscle bundles discernible at the corticomedullary junction. The distinction between adjacent reniculi was usually marked by the presence of arteries and veins but not connective tissue septa. The glomeruli and tubules had the usual mammalian arrangement. The submucosa of the base of the calyx consisted of ample vascular connective tissue. The calyx was lined by transitional epithelium which became 1 to 2 cells thick as it was reflected over the papilla. Branches of the ureter were lined by transitional epithelium and were surrounded by thick connective tissue.

Lymphoid infiltration of the submucosa and/or epithelium of the calyx was seen in the 3 seals. In addition, small interstitial lymphoid aggregates in the cortex and the connective tissue adjacent to larger vessels were present in 2 seals and the submucosa of the ureter in 1 seal.

DISCUSSION

Body weight and age

For the range of ages represented by these data, weight changes were accurately described by the exponential growth equation, $\text{weight} = w_0 r^t$, with body weight increasing by 23% per annum until at least 9–10 y of age. However, it should be noted that this growth equation has been fitted from cross-sectional data. If growth patterns have been unchanged over the lifetime of the oldest of these animals, i.e., 10 y, then the fitted growth curve will estimate the average of the growth curves of individual animals. This assumption is known as stationarity. However, many pinniped species, including the Cape fur seal, have been subject to periodic harvest (Wickens *et al.*, 1991) and compete with a growing fishing industry (Wickens *et al.*, 1992). When the effects of anthropogenic activity on pinniped populations are taken into consideration, the above assumption must be questioned. Furthermore, our limited data ($n = 30$ seals) do not show evidence of age-dependent changes in the allometric relationship. However, we would expect to find such changes in a larger sample size, e.g., rapid growth of juveniles and reduced growth at physical maturity (Stewardson, unpubl. data).

Organ size

The size of visceral organs in relation to body weight in some pinnipedia and cetacea have been discussed (Slijper, 1958; Gihl & Pilleri, 1969; Bryden, 1971, 1972; Payne, 1979). It has been shown that variation in blubber thickness attributed to age and season can have a considerable effect on relative organ weights in male pinnipeds (Schusterman & Gentry, 1971). Such limitations should be kept in mind when interpreting the significance of relative organ weights, especially when comparing results with other data sets.

Relative organ weights in adult Cape fur seals were slightly higher than percentages of body weight previously calculated for adult Antarctic fur seals (heart 0.5%; lungs 0.9%; liver 3.4%; kidneys 0.5%; spleen 0.3%) (Payne, 1979), with some exceptions. The Cape fur seal spleen was slightly smaller, and the lungs were considerably larger.

Antarctic fur seals feed predominantly on Antarctic krill, *Euphausia superba*. These pelagic crustaceans are c. 5 cm in length (small body size), form great swarms at or near the water surface (concentrated food source), and move slowly in the water column (easy to catch). The krill is usually captured at night from shallow waters. In contrast, Cape fur seals pursue large, fast prey, predominantly teleost fish. Average dive depth is generally greater when compared with Antarctic fur seals (Costa, 1991). We suggest that increased lung capacity (maximum oxygen-carrying capacity) would be advantageous to Cape fur seals because of their energetically costly foraging behaviour.

The relative size of organs was similar to those of terrestrial carnivores, although the liver and kidneys were notably larger. It has been suggested that large liver size may be a response to the high metabolic demands of deep diving, possibly facilitating the metabolism of nitrogenous products, fats and carbohydrates; whereas large kidney size is possibly related to high salt intake and the need to produce great quantities of urine (Slijper, 1958; Scheffer, 1960; Evans, 1993; Bryden 1972).

Organ growth

We have estimated the coefficient in the regression of log organ weight on log body weight. It should be noted that a different relationship would be obtained which would be represented on the graphs by a slightly steeper slope, if the regression were log body weight on log organ weight. For the present application, there is an underlying functional relationship.

For the range of ages represented in this study, organ weight increased at a rate of between 25% and 33% per annum until at least 9–10 y of age, with the exception of the intestines, where exponential increase appeared to have ceased by about 7 y. The exponents b for the lungs, stomach, intestine and kidneys were not significantly different from 1, suggesting that these organs increased in proportion to the body. However, the heart, liver and spleen had exponents $b > 1$, suggesting that these organs increased at a faster rate than the body. The functional importance of the latter organs to the general physiology of the seal is therefore of great interest, and warrants further investigation. Although slight changes may occur in those organs, whose functional significance changes during postnatal life (Bryden, 1971), small sample size prevented detection of possible differences between or within growth phases.

Although detailed information on organ growth in pinnipeds is limited, differences in the relative size and relative growth of certain organs such as the spleen, liver and kidneys, have been noted between different groups of marine mammals, and between marine mammals and terrestrial mammals (Bryden, 1972). Bryden (1971) investigated organ growth in southern elephant seals, *Mirounga leonina*; however, his study was based on fat-free body weight, thus preventing direct comparison with the present data set. Payne (1979) investigated organ growth in Antarctic fur seals, but his interpretation of growth patterns did not include statistical evidence, thus his attention has not been directed at scientifically interesting features that may be independent of sampling effects.

Gross and microscopic anatomy

Heart

The anatomy and physiology of the heart in some pinnipeds have been described (Bryden & Lim, 1969; Drabek, 1975, 1977; King, 1977, 1983). Apart from its broad, flat shape and large aortic bulb, the Cape fur seal heart resembled that of terrestrial carnivores

(Evans, 1993). Histologically, the heart was similar to other marine mammals and, like that of other pinnipeds, differed from those of cetacea in not having unusually thick endocardium and prominent Purkinje cells (Simpson & Gardner, 1972; Haldiman & Tarpley, 1993).

Lung

The multilobed lung was similar to other terrestrial carnivores (Evans, 1993), although slightly larger. The division of the lung into 4 right lobes and 2 left lobes was typical of other terrestrial carnivores, yet differed from some pinniped species. For example, the ribbon seal, *Phoca fasciata*, harp seal, *Phoca groenlandica*, and the Larga seal, *Phoca largha*, have little or no lobation (Sokolov *et al.*, 1968; Tarasoff & Kooyman, 1973; King, 1983). General features were otherwise typical of other pinnipeds (Harrison & Kooyman, 1968; Denison & Kooyman, 1973; Boshier & Hill, 1974; King, 1983).

Histological features of the lungs were typical of otariid seals (Simpson & Gardner, 1972; Denison & Kooyman, 1973), with notable features being prominent fibrous septa, prominent smooth muscle bundles and ample lymphoid tissue. Cartilaginous support extended to the level of the alveolar sacs, presumably preventing the passive collapse of airways when diving and facilitating the quick exchange of air (Kooyman & Andersen, 1969; King, 1983).

Liver

The liver was large, multilobed and had deep natural fissures. The extent of lobation appears to vary among pinniped species, with 5–8 lobes recorded within the Otariidae (Owen, 1830–31; Murie, 1874; present study). Apart from its relatively large size, and the arrangement of the caudate lobe, the liver was typical of terrestrial carnivores (Brody, 1945; King, 1983; Evans, 1993). Unlike cetaceans, a gall bladder was present in Cape fur seals.

Earlier studies examining the histological structure of the otariid liver record few special features apart from the common presence of iron pigments in hepatocytes and the presence of tall columnar, mucus secreting, bile duct epithelial cells (Simpson & Gardner, 1972; Eastman & Coalson, 1974; Britt & Howard, 1983; Lowenstine & Osborn, 1990). The presence of iron was not determined in the present study but the presence of tall columnar epithelial cells, apparently containing mucus, were present in large bile ducts.

Spleen

A typical mammalian spleen was present (Evans, 1993). Although the pinniped spleen is said to be moderately large (Slijper, 1958, 1962), percentages calculated for the adult Cape fur seal at 0.2–0.4% (present study), did not differ greatly from terrestrial mammals, at around 0.3% (Bryden, 1971). Large spleen size reported in other species of pinnipeds, such as the southern elephant seal may be a response

to the high metabolic demands of deep diving, assisting in the regulation of blood pressure and respiration (Andersen, 1966; Bryden & Lim, 1969; Gihl & Pilleri, 1969).

The histological features of the Cape fur seal spleen were similar to those previously reported in other pinnipeds (Simpson & Gardner, 1972; Schumacher & Welsch, 1987; Lowenstine & Osborn, 1990). The thick capsule, well developed trabeculae, arrangement of the red and white pulp and plentiful plasma cells found in the present study were in keeping with findings of the detailed report of Schumacher and Welsch (1987). However, eosinophils and plentiful macrophages in the marginal zone of follicles were not detected in the present study. These differences may indicate differing levels of immune stimulation, disease or parasitism; or may represent species differences. Similarly, the earlier study found evidence of erythropoiesis and thrombopoiesis in the red pulp, neither of which was conspicuous in the current study. This may be due to differences in age, as haematopoiesis has been reported elsewhere to be common in young seals (Lowenstine & Osborn, 1990); disease status or species.

Stomach

The stomach was a single chamber, with an indistinct cardia and fundus. As with other pinnipeds, digestion and absorption is a rapid process, occurring within 24–48 h (D. Miller, pers. comm.; Murie & Lavigne, 1985, 1986; Olsen *et al.*, 1996). Considering that the Cape fur seal feeds predominantly on soft food items (teleost fish and squid) which are swallowed whole, in chunks or in strips (Stewardson unpubl. data), abundant gastric glands, a small pyloric ostium and a well developed pyloric sphincter would ensure that food items are well triturated before entering the intestine (Eastman & Coalson, 1974).

General histological features of the stomach were in keeping with those previously reported for the Weddell seal (Eastman & Coalson, 1974). Abundant parietal cells have been found previously to be predominant in porpoises and sea lions (Simpson & Gardner, 1972), as they were in Cape fur seals.

Small and large intestine

The small intestine of pinnipeds is remarkably long (King, 1983). In most terrestrial carnivores the length of the small intestine to length of body is only 5–6 : 1 (King, 1983), yet in the adult Cape fur seal the ratio is 15 : 1 (present study). It has been suggested that the great length of the pinniped intestine is a response to large body size and high metabolic demands as the longer the gut, the greater is the surface area for food absorption (Bryden, 1972; Eastman & Coalson, 1974). The long guts in pinnipeds is also believed to increase the time available for enzymatic breakdown (Olsen *et al.*, 1996).

The histological organisation of the small and large intestine was typical of pinnipeds but the length of the small intestinal villi appeared excessive.

Unusually long villi were not reported in previous descriptions of the gastrointestinal tract of the Weddell seal, *Leptonychotes weddellii*, crabeater seal, *Lobodon carcinophagus*, and California sea lion (Simpson & Gardner, 1972; Eastman & Coalson, 1974; Schumacher & Welsch, 1995). As the results of the present study are based on examination of a single animal which had evidence of underlying gastrointestinal inflammation it cannot be assumed that these findings are characteristic of the species. Villous hypertrophy, distortion and fusion are lesions sometimes seen with chronic mucosal inflammation, and it cannot be ruled out that the villi of the seal in the present study were abnormal (Lee & Toner, 1980).

Kidneys

The anatomy and physiology of the kidney in some species of pinnipeds have been described (Anthony & Liouville, 1920; Depocas *et al.*, 1969; Arvy & Hidden, 1973; Bester, 1975; Vardy & Bryden, 1981; King, 1983). In the Cape fur seal, the kidney is made up of a large number of reniculi, with each unit containing a complete cortex, medulla and calyx (Bester, 1975; present study). Only pinnipeds and cetaceans have truly reniculate kidneys, presumably a response to large body size and the ability to concentrate urine (Vardy & Bryden, 1981).

The histological features of the kidney of the Cape fur seal were similar to those recorded previously (Bester, 1975). A sporta perimedullaris musculosa was not identified in the present study, nor in the study of Bester (1975); however, it is possible that collagenous and muscular tissue present at the corticomedullary junction was not identified in this study due to the sole reliance on H & E stained sections. The presence of lymphoid cells in the majority of seal kidneys examined probably indicates low grade nephritis as the presence of lymphoid cells has not been reported in previous studies of pinniped kidneys, including those of the Cape fur seal.

CONCLUSIONS

Information presented in this study contributes to earlier descriptions of the pinniped viscera, and provides new data of potential benefit to veterinary practitioners and students of mammalian physiology. The basic features of the viscera were similar to those of other otariids (Murie, 1874; Green, 1972; Odell, 1981; Vaz-Ferreira, 1981) and phocids (Owen, 1830–1831; Hepburn, 1912; St-Pierre, 1974). Apart from the liver and kidneys, relative organ size was similar to those of terrestrial carnivores, and most organs increased in proportion to body weight. Notwithstanding post mortem autolysis of some tissues and sole reliance on H & E stained sections, examination of the salient histological features of the tissues was possible. The histological organisation of the viscera was generally consistent with that previously described for this species (Denison & Kooyman, 1973; Bester, 1975; Schumacher & Welsch, 1987) and other pinnipeds (Simpson & Gardner, 1972; Lowenstine & Osborn, 1990).

ACKNOWLEDGEMENTS

We wish to thank Dr V. Cockcroft (Port Elizabeth Museum), Dr J. H. M. David (Sea Fisheries Research Institute), Dr J. Hanks (WWF-South Africa) and Prof. A. Cockburn (Australian National University) for financial and logistic support. We express our sincere appreciation to Mr B. Rose (Oosterlig Visserye, Port Elizabeth) who enabled us to collect seals from his commercial fishing vessels; Dr G. A. Waters and Mrs S. Louw (South African Medical Research Institute) for histological assistance; Mr S. Swanson (Sea Fisheries Research Institute) for assistance with dissections (AP specimens) and extracting data; and Mr N. Minch and Dr R. Barwick (Australian National University) for photographic editing. We are very grateful to Dr J.H.M. David (Sea Fisheries Research Institute) for constructive comments on the draft manuscript. The contribution of an anonymous referee is gratefully acknowledged. This paper is part of a larger study compiled on behalf of the World Wild Fund For Nature – South Africa (project ZA-348, part 2).

REFERENCES

- ANDERSEN HT (1966) Physiological adaptations in diving vertebrates. *Physiological Reviews* **46**, 212–243.
- ANTHONY R, LIOUVILLE J (1920) Les caractères d'adaptation du rein du Phoque de Ross (*Ommatophoca rossi* Gray) aux conditions de la vie aquatique. *Comptes Rendus. Academie des Sciences (Paris)* **171**, 318–320.
- ARVY L, HIDDEN G (1973) Les caractéristiques rénales et réticulaires de *Mirounga leonina*. *Comptes Rendus. Hebdomadaires des Seances. Academie des Sciences (Paris). Serie D* **277** (24), 2713–2714.
- BESTER MN (1975) The functional morphology of the kidney of the Cape fur seal *Arctocephalus pusillus* (Schreber). *Madoqua. Series II* **4**, 69–92.
- BONNER WN (1968) The fur seal of South Georgia. *Scientific Reports. British Antarctic Survey* **56**, 1–81.
- BOSHIER DP, HILL P-MGN (1974) Structural aspects of ventilation and diffusion in the Weddell seal (*Leptonychotes weddellii*). In *Functional Anatomy of Marine Mammals* (ed. Harrison RJ), vol. 2, pp. 197–229. London: Academic Press.
- BRITT JO, HOWARD EB (1983) Anatomic variants of marine mammals. In *Pathobiology of marine mammals* (ed. Howard EB), vol. 1, pp. 7–46. Boca Raton, Florida: CRC Press Inc.
- BRODY S (1945) *Bioenergetics and growth*, p. 1023. New York: Reinhold.
- BRYDEN MM (1971) Size and growth of viscera in the southern elephant seal, *Mirounga leonina* (L.). *Australian Journal of Zoology* **19**, 103–120.
- BRYDEN MM (1972) Growth and development of marine mammals. In *Functional anatomy of marine mammals* (ed. Harrison RJ), vol. 1, pp. 58–60. London and New York: Academic Press.
- BRYDEN MM, LIM GHK (1969) Blood parameters of the southern elephant seal (*Mirounga leonina*, Linn.) in relation to diving. *Comparative Biochemistry and Physiology* **28**, 139–148.
- CHAMBERS JM, HASTIE TJ (1991) *Chapman & Hall Computer Science Series: Statistical models in S*, p. 608. London: Chapman and Hall.
- COMMITTEE ON MARINE MAMMALS, AMERICAN SOCIETY OF MAMMALOGISTS (1967) Standard measurements of seals. *Journal of Mammalogy* **48**, 459–462.
- COOKE CT (1993) Drowning. In *The pathology of trauma* (ed. Mason JK), pp. 214–225. London: Edward Arnold.
- COSTA DP (1991) Reproduction and foraging energetics of pinnipeds implications for life history patterns. In *Behaviour of pinnipeds* (ed. Renouf D), pp. 300–344. London: Chapman and Hall.
- DAVID JHM (1989) Seals. In *Oceans of life off Southern Africa* (ed. Payne AIL, Crawford RJM), pp. 288–302. Cape Town: Vlaeberg Publishers.
- DENISON DM, KOOYMAN GL (1973) The structure and function of the small airways in pinniped and sea otter lungs. *Respiration Physiology* **17**, 1–10.
- DEPOCAS F, HART JS, FISHER HD (1969) Sea water drinking and water balance in the harbor seal. *American Zoologist* **9**, 587.
- DRABEK CM (1975) Some anatomical aspects of the cardiovascular system of Antarctic seals and their possible functional significance in diving. *Journal of Morphology* **145**, 85–106.
- DRABEK CM (1977) Some anatomical and functional aspects of seal hearts and aortae. In *Functional anatomy of marine mammals* (ed. Harrison RJ), vol. 3, pp. 217–234. London and New York: Academic Press Inc.
- DRURY RAB, WALLINGTON EA (1967) *Carleton's Histological Techniques*, 4th edn, p. 432. New York: Oxford University Press.
- EASTMAN JT, COALSON RE (1974) The digestive system of the Weddell seal, *Leptonychotes weddellii*-a review. In *Functional Anatomy of Marine Mammals* (ed. Harrison RJ), vol. 2, pp. 253–320. London: Academic Press.
- ENGLE ET (1926) The intestinal length in Steller's sea lion. *Journal of Mammalogy* **7**, 28–30.
- EVANS HE (1993) *Miller's anatomy of the dog*. 3rd. edn, p. 1113. Philadelphia: W. B. Saunders Company.

- FORBES WA (1882) Notes on the external characters and anatomy of the Californian sea lion (*Otaria gillespii*). *Transactions. Zoological Society of London* **11**, 225–231.
- GIHR M, PILLERI G (1969) On the anatomy and biometry of *Stenella styx* Gray and *Delphinus delphis* L. (Cetacea, Delphinidae) of the Western Mediterranean. In *Investigations on Cetacea* (ed. Pilleri G), vol. 1, pp. 15–65. Berne: Hirnanatomisches Institut der Universität.
- GREEN RF (1972) Observations on the anatomy of some cetaceans and pinnipeds. In *Mammals of the sea. Biology and Medicine* (ed. Ridgway SH), pp. 274–297. Springfield: Charles C. Thomas.
- HALDIMAN JT, TARPLEY RJ (1993) Anatomy and physiology. In *The bowhead whale* (ed. Burns JJ, Montague JJ, Cowles CJ), pp. 71–156. Lawrence, Kansas: Society for Marine Mammalogy.
- HARRISON RJ, KOOYMAN GL (1968) General physiology of the pinnipedia. In *The behaviour and physiology of pinnipeds* (ed. Harrison RJ, Hubbard RC, Peterson RS, Rice CE & Schusterman RJ), pp. 211–296. New York: Appleton-Century-Crofts.
- HEPBURN D (1912) Observations on the anatomy of the Weddell seal (*Leptonychotes weddellii*). II. Genito-urinary organs, 191–194. III. The respiratory system and the mechanism of respiration, 321–332. *Transactions. Zoological Society of Edinburgh* **48**.
- KING JE (1977) Comparative anatomy of the blood vessels of the sea lions *Neophoca* and *Phocarcotus*; with comments on the differences between the otariid and phocid vascular systems. *Journal of Zoology* (London) **181**, 69–94.
- KING JE (1983) *Seals of the world.*, 2nd edn, p. 240. London: British Museum (Nat. Hist.), Oxford University Press.
- KOOYMAN GL, ANDERSEN HT (1969) Deep diving. In *The biology of marine mammals* (ed. Andersen HT), pp. 65–94. London: Academic Press.
- LEE FD, TONER PG (1980) *Biopsy pathology of the small intestine*. pp. 69–80. London: Chapman and Hall.
- LOWENSTINE LJ, OSBORN KG (1990) Practical marine mammal microanatomy for pathologists. In *CRC handbook of marine medicine: health, disease and rehabilitation* (ed. Dierauf LA), pp. 287–290. Boca Raton, Florida: CRC Press.
- MILLER EH (1975) Body and organ measurements of fur seals, *Arctocephalus forsteri* (Lesson) from New Zealand. *Journal of Mammalogy* **56**, 511–513.
- MURIE J (1874) Researches upon the anatomy of the Pinnipedia. Part 3. Descriptive anatomy of the sea lion (*Otaria jubata*). *Transactions. Zoological Society of London* **8**, 501–582.
- MURIE DJ, LAVIGNE DM (1985) Digestion and retention of Atlantic herring otoliths in the stomachs of grey seals. In *Marine mammal-Fishery Interactions* (ed. Beddington J, Beverton RJH, Lavigne DM), pp. 292–299. London: Allen and Unwin.
- MURIE DJ, LAVIGNE DM (1986) Interpretation of otoliths in stomach content analyses of phocid seals: quantifying fish consumption. *Canadian Journal of Zoology* **64**, 1152–1157.
- ODELL DK (1981) California sea lion *Zalophus californianus* (Lesson, 1828). In *Handbook of Marine Mammals* (ed. Ridgway SH, Harrison RJ), vol. 1, pp. 67–97. London: Academic Press.
- OLSEN MA, NILSSEN KT, MATHIESEN SD (1996) Gross anatomy of the gastrointestinal system of Harp seals (*Phoca groenlandica*). *Journal of Zoology (London)* **238**, 581–589.
- OOSTHUIZEN WH (1997). Evaluation of an effective method to estimate age of Cape fur seals using ground tooth sections. *Marine Mammal Science* **13**, 683–693.
- OWEN R (1830–31) On the anatomy of the seal (*Phoca vitulina*, Linn). *Proceedings of the Royal Society of London. Series B. Biological Sciences* **1**, 151–154.
- PAYNE MR (1979) Growth in the Antarctic fur seal *Arctocephalus gazella*. *Journal of Zoology (London)* **187**, 1–20.
- SCHEFFER VB (1960) Weights of organs and glands in the northern fur seal. *Mammalia* **24**, 476–481.
- SCHMIDT-NIELSEN K (1984) *Scaling: why is animal size so important*, pp. 7–20. Cambridge: Cambridge University Press.
- SCHUMACHER U, WELSCH U (1987) Histological, histochemical, and fine structural observations on the spleen of seals. *The American Journal of Anatomy* **179**, 356–368.
- SCHUMACHER U, KLEIN P, PLÖTZ J, WELSCH U (1995) Histological, histochemical, and ultra-structural investigations on the gastrointestinal system of Antarctic seals: Weddell seal (*Leptonychotes weddellii*) and crabeater seal (*Lobodon carcinophagus*). *Journal of Morphology* **225**, 225–249.
- SCHUSTERMAN RJ, GENTRY RL (1971) Development of the fattened male phenomenon in California sea lions. *Developmental Psychobiology* **4**, 333–338.
- SHAUGHNESSY PD, BEST PB (1975) The pupping season of the Cape fur seal, *Arctocephalus pusillus pusillus*. *Sea Fisheries Branch. South Africa* Unpublished report. pp. 8.
- SIMPSON JG, GARDNER MB (1972) Comparative microscopic anatomy of selected marine mammals. In *Mammals of the sea. Biology and Medicine* (ed. Ridgway SH), pp. 298–418. Springfield: Charles C. Thomas.

SLIJPER EJ (1958) Organ weights and symmetry in porpoises and seals. *Archives Neerlandaises de Zoologie* **13**, 97–113.

SLIJPER EJ (1962) *Whales*, p. 475. London: Hutchinson.

SOKOLOV AS, KOSYGIN GM, SHUSTOV AP (1968) Lungs and trachea structure of the Bering Sea pinnipeds. *Trudy vsesoyuznyi nauchnoissledovatel'skii Institute morskogo rybnogo khozyaistva i okeanografii* **62**, 252–263.

STEWARDSON CL, BESTER MN, OOSTHUIZEN WH (1998) Reproduction in the male Cape fur seal *Arctocephalus pusillus pusillus*: age at puberty and annual cycle of the testis. *Journal of Zoology (London)* **246**, 63–74.

ST-PIERRE H (1974) The topographical splanchnology and the superficial vascular system of the Harp seal *Pagophilus groenlandicus* (Erleben, 1977). In *Functional anatomy of marine mammals* (ed. Harrison RJ), vol. 2, pp. 161–195. London: Academic Press.

TARASOFF FJ, KOOYMAN GL (1973) Observations on the anatomy of the respiratory system of the river otter, sea otter and harp seal. I. The topography, weight, and measurements of the lungs. *Canadian Journal of Zoology* **51**, 163–170.

VARDY PH, BRYDEN MM (1981) The kidney of *Leptonychotes weddellii* (Pinnipedia: Phocidae) with some observations on the kidneys of two other southern phocid seals. *Journal of Morphology* **167**, 13–34.

VAZ-FERREIRA R (1981) South American sea lion *Otaria flavescens* (Shaw, 1800). In *Handbook of Marine Mammals* (ed. Ridgway SH, Harrison RJ), vol. 1, pp. 39–65. London: Academic Press.

WARNEKE RM, SHAUGHNESSY PD (1985) *Arctocephalus pusillus*, the South African and Australian fur seal: taxonomy, evolution, biogeography, and life history. In *Studies of sea mammals in south latitudes* (ed. Ling JK, Bryden MM), pp. 53–77. Proceedings of a symposium of the 52nd ANZAAS Congress in Sydney, May 1982. South Australian Museum.

WICKENS PA (1993) Life expectancy of fur seals, with special reference to the South African (Cape) fur seal. *South African Journal of Wildlife Research* **23**, 101–106.

WICKENS PA, DAVID JHM, SHELTON PA, FIELD JG (1991) Trends in harvests and pup numbers of the South African fur seal: implications for management. *South African Journal of Marine Science* **11**, 307–326.

WICKENS PA, JAPP DW, SHELTON PA, KRIEL F, GOOSEN PC, ROSE B, *et al.*, (1992) Seals and fisheries in South Africa-competition and conflict. *South African Journal of Marine Science* **12**, 773–789.