Original Article

Placental cultures in the era of peripartum antibiotic use

Kavita BHOLA,[1] Hunaina AL-KINDI,[2] Mitali FADIA,[2] Alison L. KENT,[1] Peter COLLIGNON[3] and Jane E. DAHLSTROM[4]

[1]*Department of Neonatology,* [2]*Department of Anatomical Pathology, Australian National University Medical School,* [3]*Infectious Diseases and Microbiology, The Canberra Hospital, Australian National University Medical School, and* [4]*Department of Anatomical Pathology, The Canberra Hospital, Australian National University Medical School, Australian Capital Territory, Australia*

Background: Histological examination of the placenta can provide valuable information that aids diagnosis and management for both the mother and the fetus. Positive placental cultures may also provide the clinician with valuable information on which to base therapy.

Aims: To determine the incidence of positive placental cultures, the association with chorioamnionitis and whether the rate is affected by antibiotic administration in the peripartum period.

Methods: A retrospective study of placentas submitted for histopathology and microbiology culture in higher risk deliveries over a 12-month period in a laboratory at a tertiary facility. Data collected included gestation age, duration of rupture of membranes, maternal fever, group B *Streptococcus* status, intrapartum antibiotics, placental culture result and the histopathology result.

Results: Of the 412 placentas submitted, 25% (104 of 412) had histological evidence of *in utero* inflammation. Sixty-three percent (259 of 412) of placentas were submitted for culture. Of these, only 4.6% (12 of 259) had a positive culture result, with 75% (nine of 12) having histological evidence of acute inflammation. Group B streptococcus and *Escherichia coli* were the most common isolates. Forty-two per cent (five of 12) of these women had received peripartum antibiotics.

Conclusions: Positive placental cultures are found in only a small number of placentas with histological evidence of chorioamnionitis and funisitis. The current method of placental swabbing and culture technique is highly specific but not sensitive. The value of performing current routine placental cultures appears limited.

Key words: antibiotics, chorioamnionitis, culture, histopathology, placenta.

Introduction

Many clinicians and pathologists in the past have not valued the role of the placenta in perinatal pathology.[1] Histological examination of the placenta can provide valuable information that aids diagnosis and management for both the mother and the fetus.[2] Many pathological findings in the placenta are associated with increased morbidity and mortality in both the mother and neonate.[3]

Correspondence: Professor Jane Dahlstrom, Department of Anatomical Pathology, The Canberra Hospital, PO Box 11, Woden, ACT 2606, Australia.
Email: jane.dahlstrom@act.gov.au

Received 27 August 2007; accepted 04 December 2007.

The presence of histological chorioamnionitis is associated with increased perinatal morbidity, mostly through its association with preterm birth, but is also independently associated with neonatal death.[4] Chorioamnionitis occurs most commonly in the presence of premature rupture of membranes (PROM).[2] Wu *et al.* in their meta-analysis found that clinical chorioamnionitis was significantly associated with periventricular leukomalacia (PVL) and subsequent cerebral palsy in preterm infants and cerebral palsy in term infants.[5]

Clinical chorioamnionitis is diagnosed in 0.9–10.5% of pregnancies and may be increasing in frequency.[3] Chorioamnionitis is diagnosed less frequently on clinical grounds than by histological examination, because, in some respect, of different clinical criteria used across institutions as well as clinical practices that can alter the reliability of some of the features.[3]

	A J O	833	**Operator:** Huang Huan		**Dispatch:** 20.02.08	**PE:** Janine Budd
	Journal Name	Manuscript No.	**Proofreader:** Tang Foyu		**No. of Pages:** 184	**Copy-editor:** Mary Charlotte Fresco

Histological inflammation, however, does not by itself guarantee that infection is the cause of the process, although appears the most likely cause in the majority of cases.[6] Microorganisms have been isolated in up to 60% of placentas with histological chorioamnionitis in research studies,[7] but there is little information in respect to community-based laboratory rates of detected organisms in Australia.[3] Non-infective causes of inflammation reported include fetal hypoxia, amniotic fluid pH changes, immunological responses to fetal tissues, meconium and other non-specific reactive responses.[3]

Intrapartum antibiotics for clinical chorioamnionitis have significantly reduced the incidence of post-partum maternal complications and neonatal sepsis.[3] As a consequence, a number of large trials using antibiotics have demonstrated prolongation of pregnancy and reduced morbidity in the setting of PROM.[8–12] However, animal and human studies have also shown that administration of antibiotics does not completely eradicate bacteria from the uterus, amniotic fluid or fetus.[13,14] When low-grade infection persists despite antibiotic therapy, this may contribute to the long-term morbidity in premature infants of bronchopulmonary dysplasia, periventricular leukomalacia and cerebral palsy.[14]

Placental microbiological culture requires diligence with the sampling technique. If the external placental surface is sampled instead of the subamniotic tissue, vaginal microorganisms may contaminate the sample. Comprehensive microbiological culture methods are required to adequately culture the broad range of aerobic, anaerobic and fungi associated with *in utero* infection.[15] Although placental culture and histology may be costly and time-consuming, they may provide valuable information that may not be otherwise evident.[15]

The use of peripartum antibiotics has increased significantly. The aim of this study was to determine the incidence of positive placental cultures, the relationship with chorioamnionitis and funisitis and whether placental culture rates are affected by antibiotic administration in the peripartum period.

Methods

A retrospective review of the clinical records of women for whom placentas were submitted for histopathological examination in 2003 was reviewed, and the following data were obtained: gestational age, duration of rupture of membranes, presence of maternal fever, group B streptococcus status if known, intrapartum antibiotic use (intravenous or oral use, number of doses, type of antibiotic), placental culture results and histopathological findings.

Our institution has a policy of intrapartum antibiotic use in the following circumstances: premature rupture of membranes, premature labour (< 37 weeks gestation), rupture of membranes greater than 24 h in a term pregnancy, maternal fever in labour, group B streptococcus grown from vaginal/rectal swab or urine culture or a previous group B streptococcus-infected infant, endocarditis prophylaxis for cardiac disease, and at induction for an elective caesarean section.

Placentas were swabbed in the delivery suite according to protocol[15] and sent to microbiology for bacterial and fungal cultures, with viral cultures requested only if specifically indicated. Bacterial and fungal cultures were performed using horse blood and chocolate agar plates that were held for seven days. Swabs were also cultured using anaerobic agar plates that were held for three days and also inoculated into brain–heart infusion broths that were subcultured if turbid.

All placentas were fixed in 10% buffered formalin and processed using routine laboratory methods. At least two sections of each of the umbilical cord (one towards the maternal end and the other towards the fetal end), extraplacental membranes (including the rupture site) and a minimum of three sections of the placental plate were submitted for histological assessment. Chorioamnionitis was staged according to the original description by Naeye,[17] and funisitis staged according to the description by Lewis and Perrin.[18] Gram stain and periodic acid-Shiff (PAS) stain were performed as part of routine diagnostics if there was chorioamnionitis.

This was a retrospective quality assessment study in accordance with National Health and Medical Research Council Guidelines and as such was also covered by The Canberra Hospital Guidelines and did not require formal Ethics Committee approval.

Results

During 2003, 412 placentas were submitted for histological examination, 25% (104 of 412) had histological evidence of *in utero* inflammation. Sixty-three per cent (259 of 412) of placentas were submitted for culture according to local protocol for microbiological assessment of the placenta (Table 1). Only 12 cases (4.6%) had a positive culture result. Five of these 12 women (42%) had received peripartum antibiotics. Three of these cases were preterm deliveries. All five cases had histopathological evidence of *in utero* inflammation with chorioamnionitis and funisitis. In the seven cases with positive culture results that had not received intrapartum antibiotics, six had

Table 1 Protocol for pathological assessment of the placenta

	Microbiology	Histopathology	Cytogenetics
All preterm infants (< 37 of 40)	Yes	Yes	PRN
Prolonged rupture of membranes (> 18 h > 37 of 40)	Yes	Yes	No
Suspected maternal/fetal bacterial or viral infection	Yes	Yes	No
IUGR	No	Yes	No
Perinatal death	Yes	Yes	Yes
Pre-eclampsia	No	Yes	No
Twins	PRN	Yes	PRN
Placenta praevia	No	Yes	No

IUGR, intrauterine growth restriction; PRN, XXXXXXX.

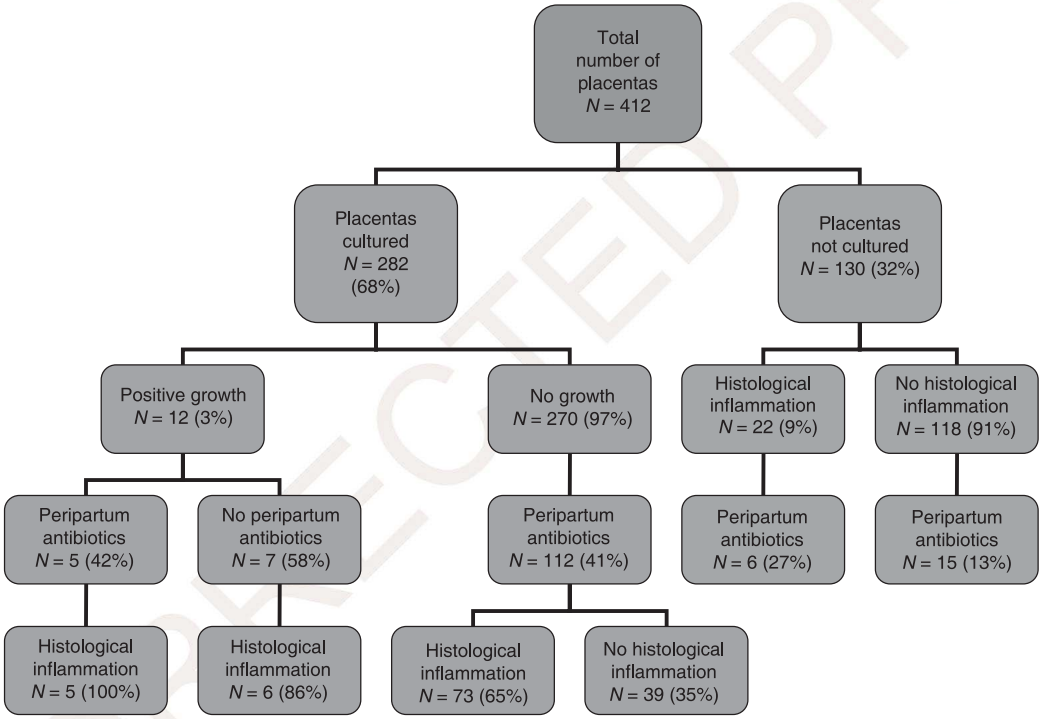

Figure 1 xxxxxxxxx.

evidence of *in utero* inflammation on histopathological evaluation (Fig. 1). There was no significant difference in gestational age in those with exposure to *in utero* inflammation and those without ($P = 0.81$).

Of the 412 placentas examined, 104 (25%) had histopathological evidence of *in utero* inflammation. Acute chorioamnionitis only was noted in 29 (28%), acute chorioamnionitis and vasculitis in 21 (20%), acute chorioamnionitis, vasculitis and funisitis in 38 (36%). Isolated vasculitis was documented in 16 cases (15%). Gram stain and PAS stain were performed as part of routine diagnostics if there was chorioamnionitis and did not show any additional organisms than those identified by culture.

Peripartum antibiotics were administered to 138 women of the 412 placentas submitted (33.5%). The organisms cultured included: group B streptococcus,[3] bacteroides,[1] *Enterobacter cloacae*,[1] *Escherichia coli*,[2] *Staphylococcus aureus*,[1] *Morganella morganii*,[1] *Coliform* spp.[1] unidentified Gram-negative bacillus[1] and Gram-positive and Gram-negative bacillus.[1] In one case where *E. coli* was cultured there was no evidence of inflammation on histological examination, and vasculitis only was noted with the case of *E. cloacae*.

Discussion

This study shows that current routine methods for placental cultures result in a low yield of growth, despite histopathological evidence of inflammation. Gram stains did not detect additional microorganisms. Positive placental cultures do not appear to be influenced by peripartum antibiotic use, although the numbers in this study are small. The reason for this low yield may be explained by either a discrepancy in the techniques of sampling and performing placental cultures, or by the fastidious nature of many of the organisms potentially causing inflammation. The one case where there was no inflammation and *E. coli* was cultured may have been a contaminant. We believe that a large percentage of these cases of *in utero* inflammation were caused by infection. Thus, the low culture rate suggests that the standard methods used in the microbiology laboratory are not sensitive enough. When group B streptococcus causes infection, the sensitivity, specificity and positive predictive values for the detection of this bacterium on Gram stain have been reported as 93, 69, and 33%, respectively.[19] Thus presumably other bacteria were frequently involved in our cases.

This study has a number of limitations that include its retrospective nature. Information that was not readily available that may confound the results include: use of antenatal steroids, the number of doses of antibiotics prior to delivery, mode of delivery, use of epidural anaesthesia, number of vaginal examinations and neonatal outcomes.

In our study, the presence or absence of intrapartum antibiotics did not appear to significantly affect the number of positive culture results, as bacteria were cultured from placentas after mothers had received antibiotics. However, the number of organisms cultured was low. When infection persists despite antibiotic treatment this is likely to be of significance to the neonate. The isolation of bacteria from an inflamed placenta by the laboratory can help the clinician in choosing the most appropriate antibiotic treatment.

When a placenta is submitted to the laboratory, histological examination in our hospital is uniform and performed by pathologists who strictly follow the descriptions of Naeye.[17] The presence of histopathological inflammation in 24% of cases reflects the selectiveness and thus the high-risk population from whom these placentas were submitted.

Our results question whether placental cultures should be undertaken, given the very low yield of positive results (4%). Histological examination was much more productive at identifying evidence of inflammation (which we presume is mainly due to infection) and thus may identify those infants at risk of long-term neurological morbidity. Histology may also help identify bacteria that will not grow on culture (although that did not occur in this study). However, when a positive culture result does occur, this does help direct appropriate antibiotic therapy as well as duration of treatment and thus may potentially improve the neonatal outcome.

Ventolini *et al.* concluded that routine placental examination is not indicated in low-risk, singleton, term pregnancies unless the placenta is determined to be abnormal on macroscopic examination after delivery.[20] Our data would support this conclusion. The American College of Pathologists have provided a consensus statement on indications for placental examination.[21] However, there are no accepted guidelines in Australia for when a placenta should be submitted for pathological examination or placental culture.[22]

Administration of antibiotics in patients with preterm premature rupture of membranes is associated with a significant reduction in the incidence of histological chorioamnionitis, although this does not appear to modify the frequency of funisitis.[23] Funisitis represents a fetal response to infection and may place the neonate at greater risk of morbidity and mortality. Administration of antibiotics to the mother in labour with risk factors results in a decreased incidence of neonatal sepsis.[24] Antibiotic administration after PROM decreases both maternal and neonatal morbidity.[8–12] As a consequence, the use of peripartum antibiotics has an important role in perinatal care.

Given that the current method of routine placental cultures has a low yield, yet we believe that infections are still likely to be the main cause, more sensitive methods of microbiological techniques need to be considered. Polymerase chain reaction (PCR) using primers against the bacterial 16S ribosomal RNA genes (16S rRNA) can be used to amplify any bacterial DNA. Universal bacterial PCR does not rely on culture of the bacteria and requires no pre-existing phylogenetic information. The rapidly expanding use of 16S rRNA sequences for phylogenetic, evolutionary, and diagnostic studies offers an opportunity for an alternative approach to bacterial detection,[25] and has been successfully used to detect intra-amniotic infection from fetal membranes.[26] 16S rRNA gene nucleotide sequencing has been found to assist in identification of bacteria from heart valve tissue.[27] Subsequent sequencing of the amplified product can also then identify the causative bacteria of the infection. The facilities to perform these tests are not currently available in most routine laboratories mainly because

of costs, but, if available, would allow better targeted antibiotic therapy for those mothers and neonates who need therapy. Although PCR will not provide sensitivities to the organism, it may find organisms that would not necessarily be covered by the usual regimen of antibiotics.

Conclusion

The current method of placental swabbing, culture and Gram stain by microbiology laboratories appears to be highly specific but lacks sensitivity. Although the yield by culture is low, a positive result, however, remains very useful clinically to the neonatal practitioner and until other options such as 16S RNA amplification are available, we would not advocate ceasing placental cultures. Histological examination detected inflammation in a high percentage of placenta sent for examination, and should continue to be performed in all high-risk births.

Acknowledgements

We would like to thank the staff in the Department of Anatomical Pathology, especially Amanda Bullman, for their contribution to this study.

References

1 Altshuler G. Role of the placenta in perinatal pathology (revisited). *Pediatr Pathol Lab Med* 1996; **16**: 207–233.
2 Beebe LA, Cowan LD, Hyde SR, Altshuler G. Methods to improve the reliability of histopathological diagnosis in the placenta. *Paediatr Perinatal Epidemiol* 2000; **14**: 172–178.
3 Smulian JC, Shen-Schwarz S, Vintzileos AM, Lake MF, Ananth CV. Clinical chorioamnionitis and histologic placental inflammation. *Obstet Gynecol* 1999; **94**: 1000–1005.
4 Elimain A, Verma U, Beneck D, Cipriano R, Visintainer P, Tejani N. Histologic chorioamnionitis, antenatal steroids, and perinatal outcomes. *Obstet Gynecol* 2000; **96**: 333–336.
5 Wu YW, Colford JM. Chorioamnionitis as a risk factor for cerebral palsy: A metaanalysis. *JAMA* 2000; **284**: 1417–1424.
6 Goldenberg RL, Hauth JC, Andrews WW. Intrauterine infection and preterm delivery. *N Engl J Med* 2000; **342**: 1500–1507.
7 Hillier SL, Martius J, Krohn M, Kiviat N, Holmes KK, Eschenbach DA. A case-control study of chorioamnionic infection and histologic chorioamnionitis in prematurity. *N Engl J Med* 1988; **319**: 972–978.
8 August Fuhr N, Becker C, van Baalen A, Bauer K, Hopp H. Antibiotic therapy for preterm premature rupture of membranes – Results of a multicenter study. *J Perinat Med* 2006; **34**: 203–206.
9 Mercer BM, Miodovnik M, Thurnau GR *et al.* Antibiotic therapy for reduction of infant morbidity after preterm premature rupture of the membranes. A randomized controlled trial. National Institute of Child Health and Human Development Maternal-Fetal Medicine Units Network. *JAMA* 1997; **278**: 989–995.
10 McGregor JA, French JI, Seo K. Antimicrobial therapy in preterm premature rupture of membranes: Results of a prospective, double-blind, placebo-controlled trial of erythromycin. *Am J Obstet Gynecol* 1991; **165**: 632–640.
11 Kenyon SL, Taylor DJ, Tarnow-Mordi W, ORACLE Collaborative Group. Broad-spectrum antibiotics for preterm, prelabour rupture of fetal membranes: The ORACLE I randomised trial. ORACLE Collaborative Group. *Lancet* 2001; **357**: 979–988.
12 Kenyon S, Boulvain M, Neilson J. Antibiotics for preterm rupture of membranes. *Cochrane Database Syst Rev* 2003; (2): CD001058. Review.
13 Gibbs RS, Davies JK, McDuffie RS *et al.* Chronic intrauterine infection and inflammation in the preterm rabbit, despite antibiotic therapy. *Am J Obstet Gynecol* 2002; **186**: 234–239.
14 Gomez R, Romero R, Nien JK *et al.* Antibiotic administration to patients with preterm premature rupture of membranes does not eradicate intra-amniotic infection. *J Matern Fetal Neonatal Med* 2007; **20**: 167–173.
15 Vigneswaran R, Aitchison SJ, McDonald HM, Khong TY, Hiller JE. Cerebral palsy and placental infection; a case cohort study. *BMC Pregnancy Childbirth* 2004; **4**: 1.
16 http://www.wch.sa.gov.au.
17 Naeye RL. Functionally important disorders of the placenta, umbilical cord, and fetal membranes. *Hum Pathol* 1987; **18**: 680–691.
18 Lewis SH, Perrin E. *Pathology of the Placenta*, 2nd edn. London, UK: Churchill Livingstone, 1999; 318–320.
19 Holls WM, Thomas J, Troyer V. Cervical Gram stain for rapid detection of colonization with beta-streptococcus. *Obstet Gynecol* 1987; **69**: 354–357.
20 Ventolini G, Samlowski R, Hood DL. Placental findings in low-risk, singleton, term pregnancies after uncomplicated deliveries. *Am J Perinatol* 2004; **21**: 325–328.
21 Langston C, Kaplan C, Macpherson T *et al.* Practice guideline for examination of the placenta. Developed by the placental pathology practice guideline development task force of the College of American Pathologists. *Arch Path Lab Med* 1997; **121**: 449–476.
22 Badawi N, Kurinczuk JJ, Chambers HM, Stanley FJ. Why is the placenta being ignored ? *Aust N Z J Obstet Gynaecol* 2000; **40**: 343–346.
23 Ovalle A, Martinez MA, Kakarieka E *et al.* Placental histopathology in premature rupture of membranes. Its relationship with microbiological findings,

maternal, and neonatal outcome. *Rev Med Chil* 1998; **126**: 930–942.
24 Gilstrap LC III, Leveno KJ, Cox SM, Burris JS, Mashburn M, Rosenfeld CR. Intrapartum treatment of acute chorioamnionitis: Impact on neonatal sepsis. *Am J Obstet Gynecol* 1988; **159**: 579–583.
25 Fredricks DN, Relman DA. Application of polymerase chain reaction to the diagnosis of infectious diseases. *Clin Infect Dis* 1999; **29**: 475–488.
26 Cahill RJ, Tan S, Dougan G *et al.* Universal DNA primers amplify bacterial DNA from human fetal membranes and link Fusobacterium nucleatum with prolonged preterm membrane rupture. *Mol Hum Reprod* 2005; **11**: 761–766.
27 Imrit K, Goldfischer M, Wang J *et al.* Identification of bacteria in formalin-fixed, paraffin-embedded heart valve tissue via 16S r RNA gene nucleotide sequencing. *J Clin Microbiol* 2006; **44**: 2609–2611.

Author Query Form

Journal: Australian and New Zealand Journal of Obstetrics and Gynaecology

Article: ajo_833

Dear Author,

During the copy-editing of your paper, the following queries arose. Please respond to these by marking up your proofs with the necessary changes/additions. Please write your answers on the query sheet if there is insufficient space on the page proofs. Please write clearly and follow the conventions shown on the attached corrections sheet. If returning the proof by fax do not write too close to the paper's edge. Please remember that illegible mark-ups may delay publication.

Many thanks for your assistance.

No.	Query	Remarks
1	Author: Please check if 'reviewed' is the correct term here as the sentence would read 'A retrospective review ... was reviewed ...'	
2	Author: Please indicate where reference no. 16 is to be cited in the text.	
3	Author: Please supply definition for PRN here.	
4	Author: Please supply legend for Figure 1.	
5	Author: Perhaps 'detect' is a better word than 'find' here?	